



FSBEI HE Prof. V.F. Voino-Yasenetsky KrasSMU MOH Russia
Department of faculty surgery named after professor Yu.M.Lubensky
Head of the Department: Dr.Med.Sc. Assoc.Prof. Zdzitovetskiy Dmitriy Eduardovich

COMPLICATIONS OF GASTRIC AND DUODENAL ULCER

BLEEDING

PERFORATION

Lecture for 4th grade students
in speciality 31.05.01 «General Medicine»

Cand.Med.Sc. Assoc.Prof. Borisov Roman Nikolaevich

LECTURE PLAN

- ▶ Basics of gastric and duodenal anatomy
- ▶ **GASTRODUODENAL ULCER BLEEDING**
- ▶ Classifications
- ▶ Clinical picture of ulcer bleeding
- ▶ Diagnosis of bleeding
- ▶ Therapeutic and surgical tactics
- ▶ **PERFORATED ULCERS OF STOMACH AND DUODENUM**
- ▶ Classification
- ▶ Clinical picture of perforated ulcer, periods of clinical course
- ▶ Diagnosis of perforated ulcer
- ▶ Surgical tactics



COMPLICATIONS OF ULCERATIVE DISEASE

- **Bleeding**
 - **Perforation**
 - **Penetration**
 - **Stenosis**
 - **Malignant degeneration**
- 



INDICATIONS TO SURGERY

VITAL

- Perforation
- Continued bleeding

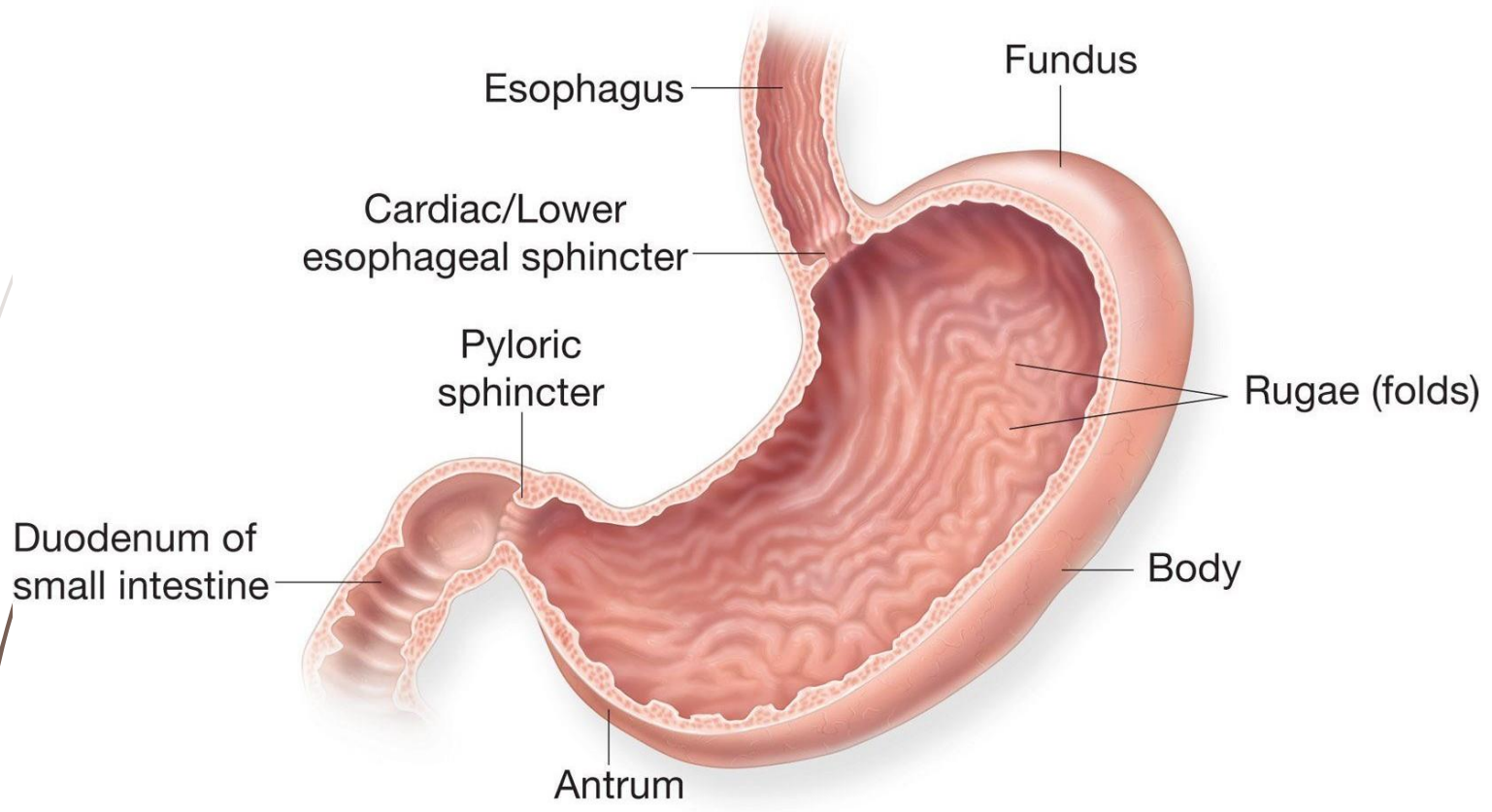
ABSOLUTE

- Malignant degeneration
- Decompensated stenosis
- Repeated bleeding
- Covered perforations

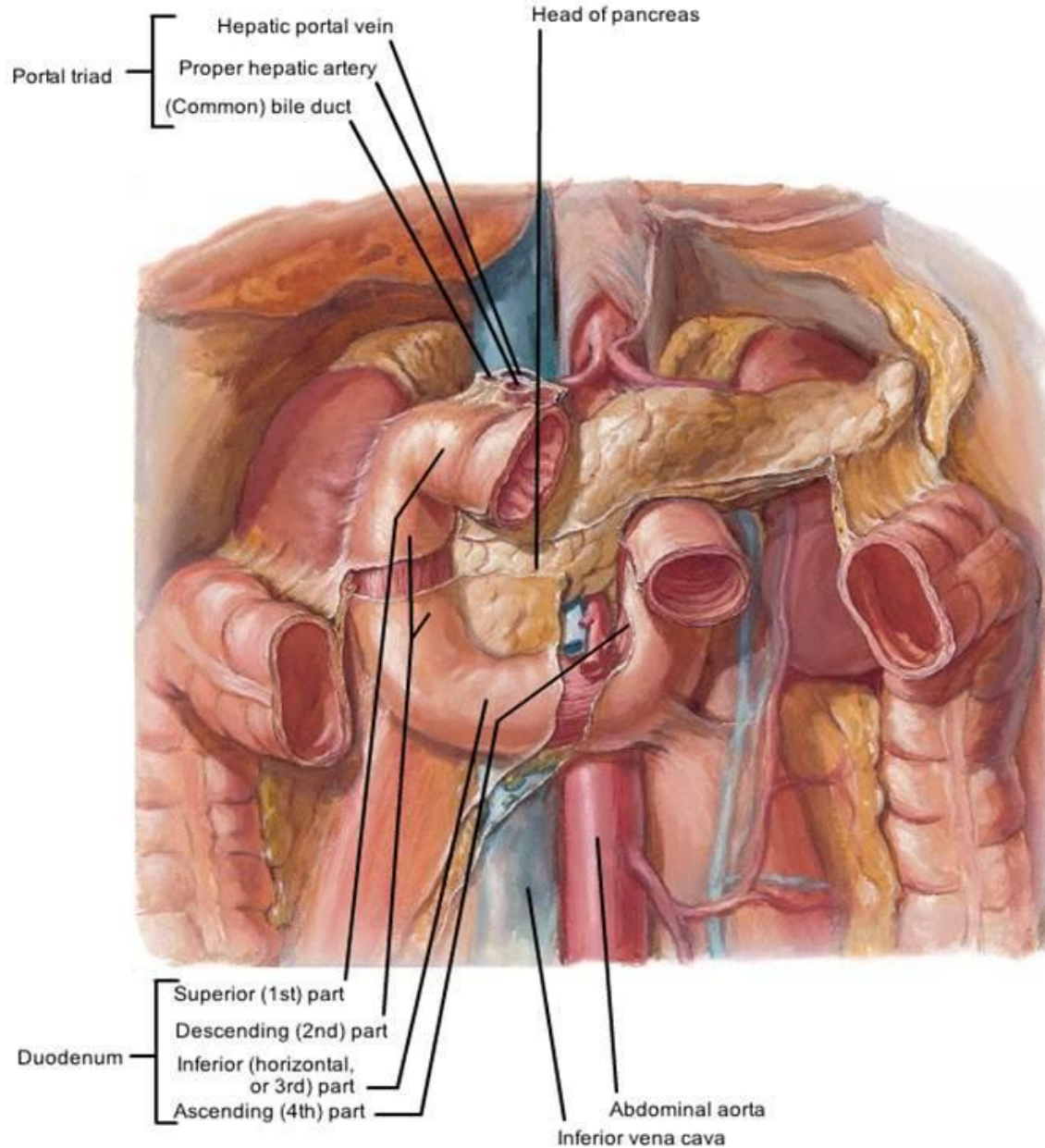
RELATIVE

- Penetration
- Chronic callous ulcers
- Cicatricial deformation of stomach and duodenum
- Inefficacy of conservative treatment

STOMACH

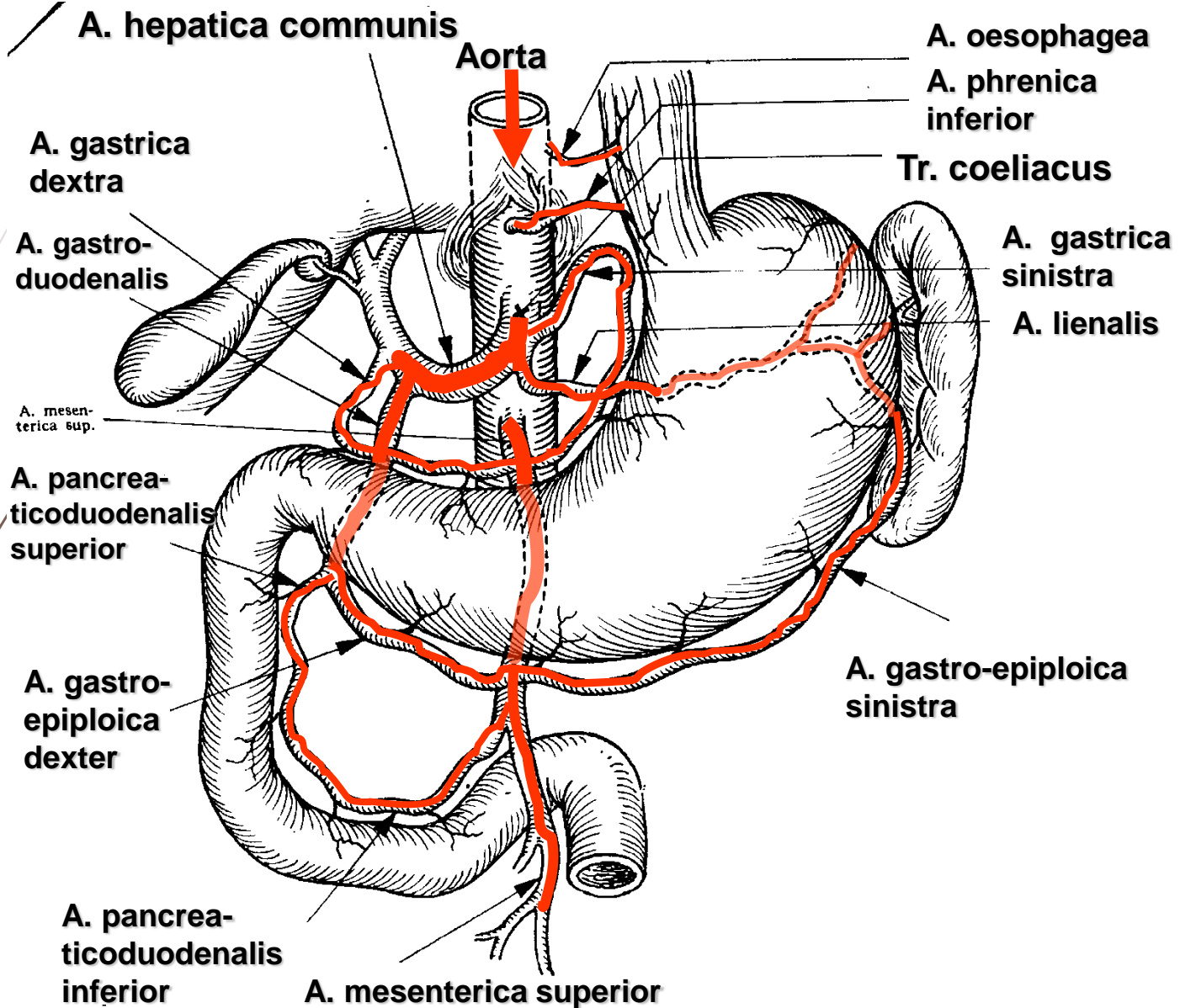


DUODENUM



F. Netter
M.D.

BLOOD SUPPLY OF THE STOMACH AND THE DUODENUM

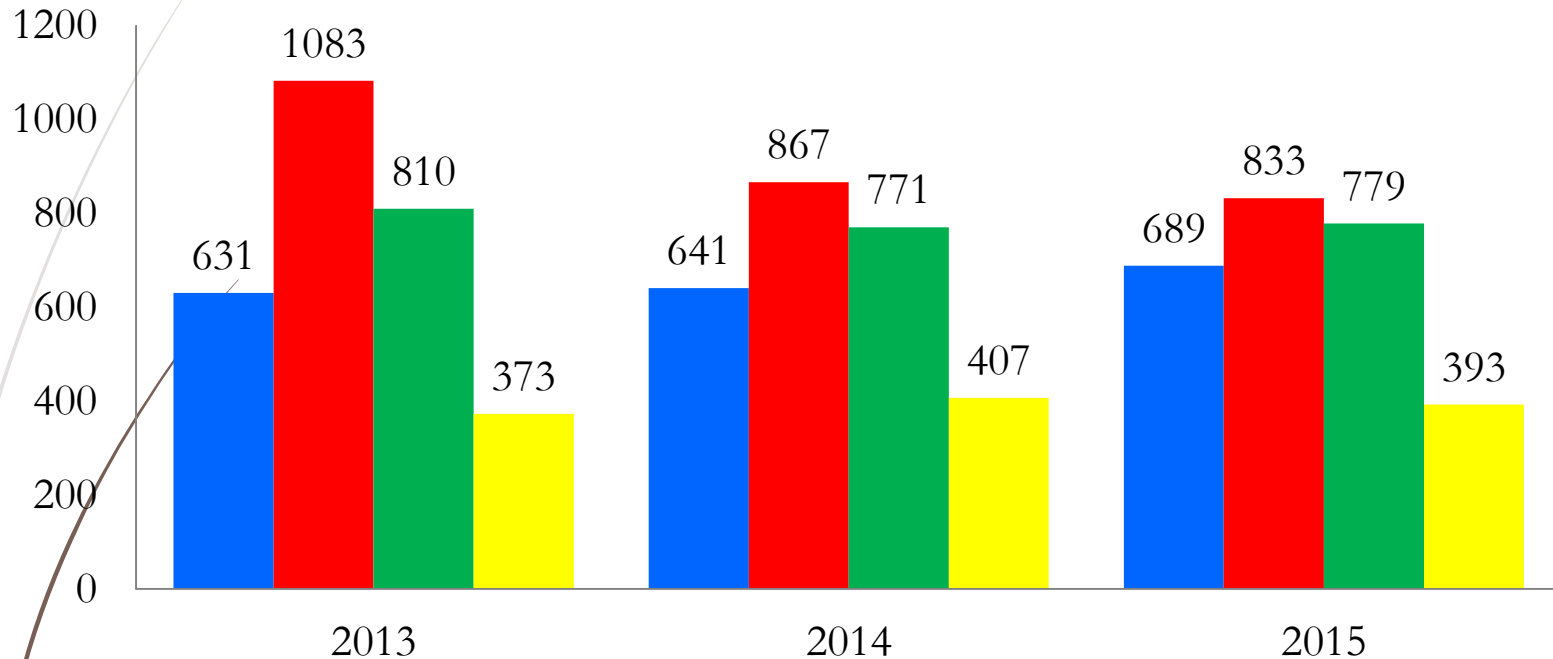


Gastroduodenal ulcer bleeding

- Incidence of ulcerative disease in the Russian Federation is 1.7-5% of the population
- Frequency of bleeding in ulcerative disease is 90-160 in 100,000 of the population
- Gastroduodenal ulcer bleeding amounts to 50% of all bleedings in the gastrointestinal tract
- Occurs 2.5-3 times more often in men than in women
- Overall case fatality rate is 5-7%
- Postoperative case fatality rate in severe bleeding amounts to 15-50%

Structure of acute surgical pathology

(according to data from Krasnoyarsk Interdistrict Clinical Hospital of Emergency Medical care named after N.S. Karpovich for the period of 2013-2015)



- Acute appendicitis
- Acute pancreatitis
- Acute diseases of the gall bladder and bile ducts
- Upper gastrointestinal bleeding

Upper gastrointestinal bleeding

(according to data from Krasnoyarsk Interdistrict Clinical Hospital of Emergency Medical care named after N.S. Karpovich for the period of 2013-2015)

Cause of bleeding	Number of patients	Surgical activity	Case fatality rate
	Abs. (%)		
Ulcers	602 (51.3)	39 (6.5)	38 (6.3)
Mallory-Weiss syndrome	244 (20.8)	4 (1.6)	69 (28.3)
Varicose veins dilation	165 (14.1)	38 (23.0)	7 (4.2)
Erosions	162 (13.8)	0	11 (6.8)
Total	1173 (100.0)		

Gastroduodenal ulcer bleeding

- **Chronic ulcer (ulcerative disease)**
- **Acute ulcers**
- **Stress ulcers**
- **Symptomatic ulcers**
- **NSAID-associated ulcers (“aspirin-induced”)**
- **Zollinger–Ellison syndrome**
- **Gastroduodenal ulcer bleeding**

Gastroduodenal ulcer bleeding

- ▶ Most often, massive life-threatening bleedings occur from callous ulcers of the lesser curvature of stomach and medial posterior part of the duodenal bulb, which is associated with the specific of blood supply to these region
- ▶ The source of bleeding in ulcerative disease may be eroded vessels of different diameter (from small vessels to large branches of the left gastric artery and the gastroduodenal artery) located at the bottom of the ulcer as well as the margins of the ulcer crater with diffuse bleeding due to inflammatory and destructive changes in the wall of the organ

Gastroduodenal ulcer bleeding

- ▶ Recurrent peptic ulcers after gastric resection are usually located on the jejunum in the area of gastroenteroanastomosis (in the duodenum in case of organ-sparing surgery) or, less often, in the stomach itself
- ▶ The most persistent bleeding occurs in recurrent ulcers, an important factor in pathogenesis of which is hypergastrinemia (unreasonably sparing excision of the organ during gastric resection, a remaining part of the antrum or **Zollinger-Ellison syndrome** undiagnosed before surgery)

Gastroduodenal ulcer bleeding.

Clinical manifestations.

- **General manifestations of blood loss, independently from its source:**
 - *acute generalised weakness*
 - *vertigo*
 - *tinnitus*
 - *floaters*
 - *cold sweat*
 - *heart beating*
 - *loss of consciousness*
 - *tachycardia, hypotension*
- **General manifestations of blood loss into the upper gastrointestinal tract:**
 - *vomiting with fresh or changed “coffee grounds” blood*
 - *melena* or *haematochezia*

Gastroduodenal ulcer bleeding.

Clinical manifestations.

Local manifestations of bleeding

- ▶ During bleeding, vomiting occurs in the proximal section of the stomach: “coffee grounds” first and non-changed blood with clots later
- ▶ Prepyloric area and antrum: vomiting only with “coffee grounds”
- ▶ In case of post-pyloric source of bleeding: tarry stool; vomiting with “coffee grounds” does not occur if there is absence of profuse reflux of blood into the stomach through the pylorus

Gastroduodenal ulcer bleeding.

Medical history of the disease.

- ▶ Thorough questioning of the patient often makes it possible to reveal a long-term history of ulcerative disease, treatment in inpatient facilities, earlier cases of gastric bleeding as well as surgeries on the stomach, e.g. for perforated ulcer
- ▶ It is possible to reveal characteristic dyspeptic phenomena, specifics in abdominal pain associated with food intake, seasonality of disease recurrence

Gastroduodenal ulcer bleeding.

Medical history of the disease.

- ▶ Bleeding is preceded by occurrence of pain in the epigastric region, exacerbation of ulcerative disease
- ▶ **Bergman's sign:** abdominal pain disappears immediately before bleeding
- ▶ Disappearance of pain in the epigastrium after bleeding is a permanent symptom

Gastroduodenal ulcer bleeding.

Physical examination data.

- ▶ Pallor of skin and visible mucosae, pronounced visibility of subcutaneous vein pattern is noticeable
- ▶ The abdomen may be slightly inflated, more often retracted
- ▶ Soft abdomen upon palpation
- ▶ Pain in the epigastrium is determined only upon penetration of the ulcer or its perforation in combination with bleeding
- ▶ As a rule, the heart rate is accelerated, with poor volume
- ▶ Lowered ABP

Gastroduodenal ulcer bleeding.

Rectal examination.

- ▶ In ulcer bleeding, black tarry stool is observed
- ▶ In massive gastric bleeding, it is possible to find slightly changed blood of dark-cherry colour

Gastroduodenal ulcer bleeding.

Severity grades.

Parameters	Mild	Moderate	Severe
CBV loss, % (ml)	10-20 (< 1000)	20-30 (< 2000)	> 30 (2000-2500)
Haemoglobin, g/l	≥ 100 и более	80-100	< 80
Platelets, x10 ¹² /l	≥ 3.5 и более	2.5-3.5	< 2.5
Haematocrit, %	≥ 30 и более	25-30	< 25
HR, beats/min	< 100	< 110	≥ 120
ABP, mm Hg	Normal	90	< 90
Allgower shock index, HR/ABPs	0.65	1.0	1.5-2.0

Clinical guidelines on management of patients at the pre-hospital stage

- ▶ All patients with gastroduodenal ulcer bleeding must be hospitalised in a surgical inpatient facility or ICU
- ▶ Introduction of proton pump inhibitors at the pre-hospital stage is possible
- ▶ Permanent nasogastric intubation is recommended
- ▶ To determine the severity of blood loss, it is recommended to use assessment scales (A.I. Gorbashko, 1974) CBV parameters
- ▶ Severe blood loss requires hospitalisation in the ICU
- ▶ Protocols for clinical examination of patients with gastroduodenal ulcer bleeding required for laboratory and instrumental analysis are to be standardised by each healthcare facility individually

Gastroduodenal ulcer bleeding.

Laboratory and functional diagnosis.

- ▶ **Urgent complete blood count:**

- ▶ decrease in haemoglobin level
- ▶ decrease in erythrocyte count
- ▶ decrease in haematocrit
- ▶ white blood cell differential
- ▶ platelet count

- ▶ **The true anaemia severity is only clear after a day or longer has passed, when haemodilution has developed**

Gastroduodenal ulcer bleeding.

Laboratory and functional diagnosis.

- ▶ **The severity of the patient's condition and their individual reactions to the blood loss are quite clearly characterised by:**
 - ▶ haemodynamic parameters:
 - ▶ CVP
 - ▶ central haemodynamic parameters
 - ▶ oxygen transport parameters:
 - ▶ PO₂
 - ▶ oxygen transport per minute
 - ▶ metabolic parameters:
 - ▶ blood urea
 - ▶ electrolytes
 - ▶ acid-base balance
 - ▶ plasma osmolarity, etc.
- ▶ **All these data determined repeatedly are of large significance for compiling a plan for intensive care**

Gastroduodenal ulcer bleeding.

Laboratory and functional diagnosis.

- ▶ Impairment of blood coagulation system parameters:
 - ▶ longer coagulation time and bleeding time
 - ▶ decrease in the level of prothrombin and fibrinogen
- ▶ The blood loss itself, especially severe, may lead to hypocoagulability
- ▶ High bilirubin values attest to the possible hepatic cirrhosis or haemobilia

Gastroduodenal ulcer bleeding.

Instrumental diagnosis.

Endoscopic manifestations of haemorrhage according to Forrest (1974):

- ▶ Type I - active haemorrhage:
 - ▶ I a - *arterial haemorrhage from the ulcer*
 - ▶ I b - *oozing torrent bleeding from the ulcerative defect*
- ▶ Type II - signs of recent bleeding (ulcer with a thrombosed vessel at the bottom)
 - ▶ II a - *visible (non-bleeding) vessel*
 - ▶ II b - *an adherent thrombus - a clot*
 - ▶ II c - *flat black stain (black base of the ulcer)*
- ▶ Type III - ulcer with a clean (white) base

Gastroduodenal ulcer bleeding.

Instrumental diagnosis.

- ▶ Radiological examination as a method for urgent diagnosis gastrointestinal bleeding has presently receded into the background
- ▶ It is mainly used after arrest of bleeding as a method for additional diagnosis of morphologic changes and motor-evacuation function of the gastrointestinal tract
- ▶ It makes it possible to obtain positive data in 80% of the cases, especially in such diseases as bleeding ulcer, tumours, varicose veins dilation

Gastroduodenal ulcer bleeding.

Diagnostic and therapeutic EGDS.

- **EGDS within the first 2 hours after hospitalisation!**
- **Stratification of patients according to the classification by J.F. Forrest (1974)**
 - For F-1a, F1-b, endoscopic haemostasis is indicated
 - For F-2a, F-2b, endoscopic prevention of bleeding recurrence is recommended
 - The clot at the base of the ulcer is recommended to be removed through irrigation with subsequent treatment of the ulcer
 - The injection method as monotherapy is inefficacious!
 - Methods of choice: injection method + diathermocoagulation (or APC or clipping)
 - Indications to repeated EGDS: incomplete primary examination, unstable haemostasis, recurrence of haemorrhage

Gastroduodenal ulcer bleeding.

Conservative treatment.

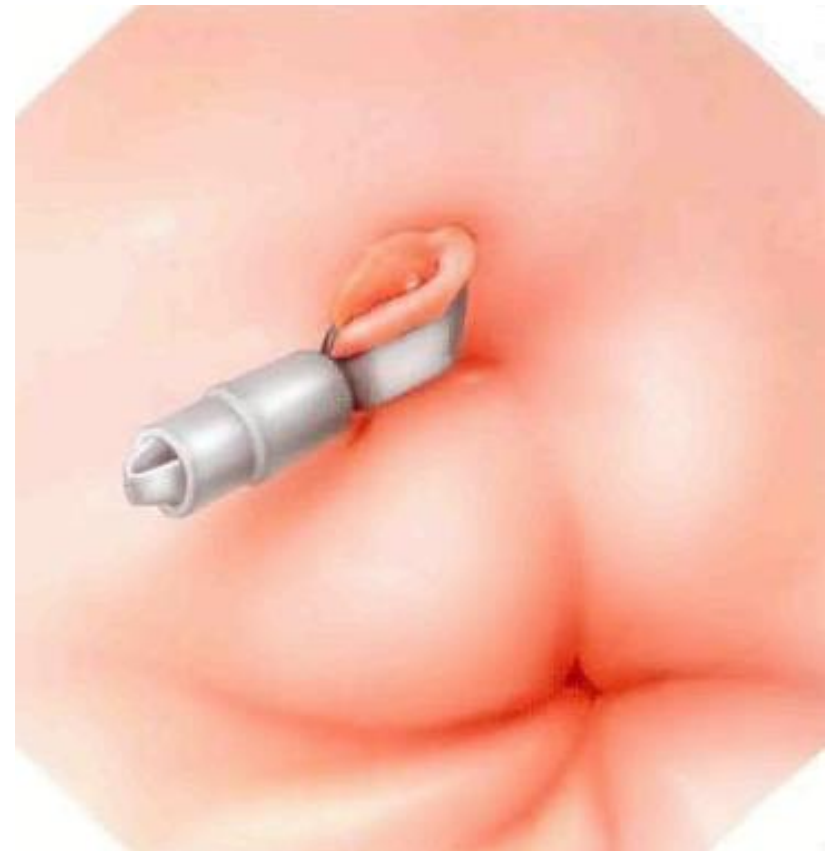
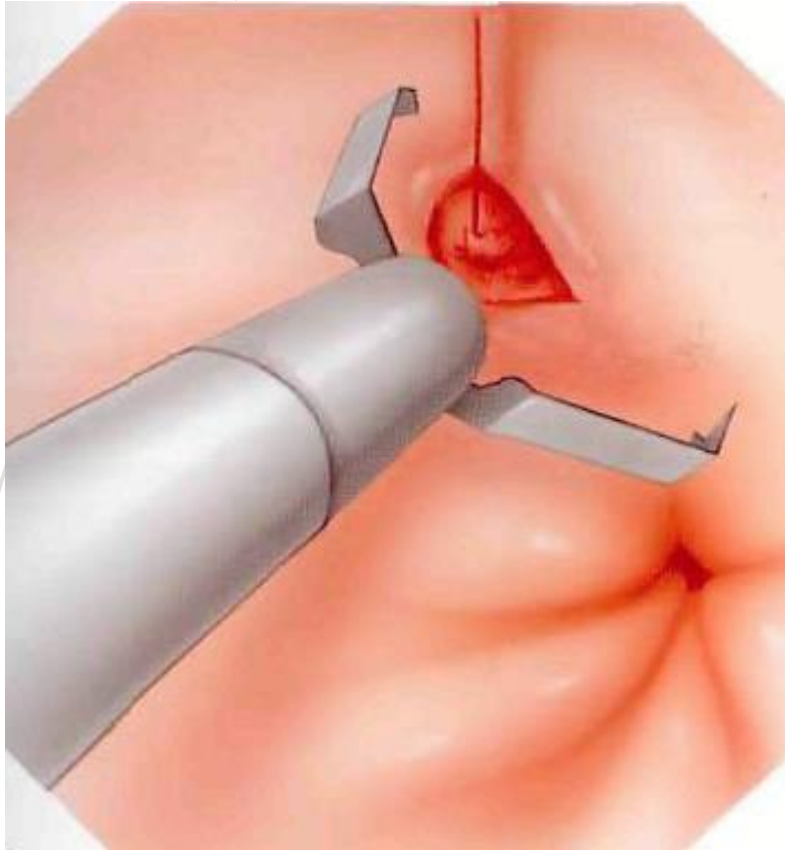
- ▶ I/V bolus of proton pump inhibitors with subsequent continuous infusion after endoscopic haemostasis for 72 hours
- ▶ from day 3: conversion to peroral forms of proton pump inhibitors
- ▶ application of H₂-blockers and octreotide is not recommended!
- ▶ all patients are to be examined in regard to presence of HP infection and, in case of its presence, to undergo eradication therapy at the inpatient facility!
- ▶ haemotransfusion at Hb < g/l
- ▶ it is possible to use Perftoran, extrapulmonary oxygenation

Gastroduodenal ulcer bleeding.

Endoscopic haemostasis.

- ▶ mono- and biactive diathermocoagulation
- ▶ argon plasma coagulation
- ▶ injection methods for introduction of adrenaline, absolute ethanol and its solutions, sclerosants
- ▶ application of film forming polymers (Tachocomb, Feracryl, Caprofer, etc.)
- ▶ endoligation
- ▶ endoclipping

Endoscopic haemostasis



Gastroduodenal ulcer bleeding.

Surgical treatment.

INDICATIONS TO URGENT SURGERY

- ▶ continuing bleeding in inefficacy (or impossibility) of endoscopic haemostasis
- ▶ **recurrence of bleeding** (*possible repeated endoscopic haemostasis and transcatheter embolization of gastric and duodenal arteries*)



Gastroduodenal ulcer bleeding.

Surgical treatment.

INDICATIONS TO EMERGENCY SURGERY

- ▶ High risk of bleeding recurrence

Gastroduodenal ulcer bleeding.

Surgical treatment.

- *Prognosis of bleeding recurrence* is based on:
 - **clinical and laboratory data:**
 - signs of haemorrhagic shock
 - profuse vomiting and/or massive melena
 - globular volume deficit corresponding with severe blood loss
 - **results of endoscopic examination:**
 - continuing arterial bleeding at the moment of examination
 - large thrombosed vessels in the ulcer crater
 - ulcerative defect of a large diameter and depth
 - localisation of the ulcer in the projection of large vessels
- Presence of any two of the adverse factors is considered as evidence to the present danger of repeated bleeding

Gastroduodenal ulcer bleeding.

Surgical treatment.

SURGERIES FOR GASTRIC ULCER

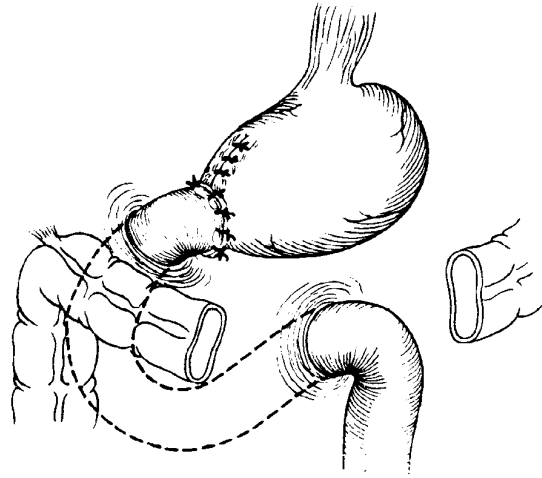
- ▶ Gastrotomy, suturing of the bleeding vessel (*high surgical risk*)
- ▶ Gastric resection

SURGERIES FOR DUODENAL ULCER

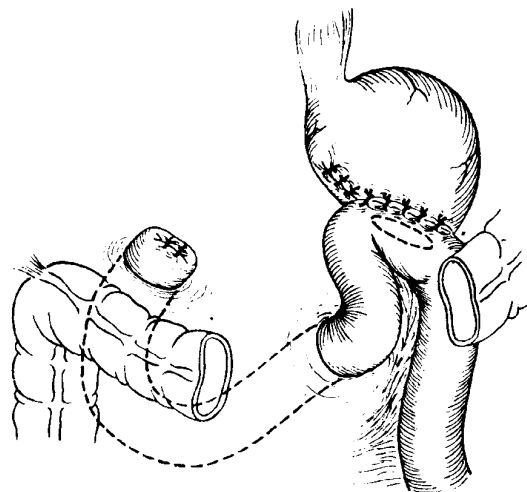
- ▶ Duodenotomy with suturing of the bleeding vessel at the ulcer base (*in critical condition*)
- ▶ Pyloroduodenotomy with excision of anterior wall ulcer (*or suturing of the posterior wall*), Finney pyloroplasty and stem vagotomy
- ▶ Gastric resection

Surgical treatment

Gastric resection




Billroth I



Billroth II



!?



Perforated ulcers of stomach and duodenum

- ▶ Perforation is an acute surgical disease resulting from perforating destruction of the gastric or duodenal wall in the area of ulcer.
- ▶ The frequency of this complication in ulcerative disease patients varies from 2 to 10% (duodenal ulcers perforate more often: up to 75% of the patients, as well as ulcers of prepyloric and pyloric localisation; less often: gastric ulcers, up to 5%).
- ▶ The age of patients with perforation is 40-60 years, with medical history of ulcer below 3 years and it may be completely absent in 25% of the patients

Perforated ulcers of stomach and duodenum

- ▶ Prevail in male patients (the ratio between men and women with this complication is 2:1, with 7-10-fold predominance of males in young subjects)
- ▶ Usually, in autumn or spring, during wars and economic crisis the frequency of perforation grows by 2 times
- ▶ For young subjects, ulcerative perforation is usually in duodenum (85%), and in stomach for the elderly

Historical background

- ▶ The first reports on complications of gastric ulcer: XVII century (in 1695, Grossius described perforated ulcers)
- ▶ 1830: the first detailed description of the clinical picture, diagnosis methods and treatment outcomes (with mentioning of the “corrosive process ending in perforation of the stomach”) (Cruveilhier)
- ▶ 1831: the report title “Corroding of the stomach” (Karsvel, Russia): an opinion is given on corrosive action of gastric juice on the gastric wall. **Treatment with opium and poultice on the abdomen** (with low treatment efficacy)

Historical background

- 1880: the first surgery for suturing of perforated ulcer (Mikulicz) with a lethal outcome
- 1892: the first successful surgery for suturing of perforated ulcer (Heussner)
- In Russia, the first suturing of perforated ulcer was performed by R.Kh. Vanakh (1897)
- V.A. Oppel (1896) proposed application of omentum with a pedicle for closure of the perforation orifice
- In 1902, Keeriy performed first successful gastric resection in perforated ulcer
- 1909: at the congress of Russian surgeons, a decision was made regarding the transfer of patients with clinical picture of perforation directly to surgeons (a decrease in case fatality rate in the postoperative period)

Historical background

- ▶ Taylor (1946) introduced into practice the conservative method of treatment of perforated ulcers with continuous aspiration of the gastric contents
- ▶ Weinberg (1960), Hinshaw, Pierandozzi (1960, 1968) recommended vagotomy with pyloroplasty and excision of the ulcer
- ▶ 1940th: surgical treatment experience has been accumulated in the USSR (postoperative case fatality rate of 16%). A large contribution in development of surgery for gastroduodenal ulcer was made by S.S. Yudin, Yu.Yu. Dzhanlidze, A.V. Melnikov and I.I. Neymark
- ▶ 1980th: in the USSR, 12 surgeries in 100,000 of the population were performed annually (approximately 35,000 surgeries per year)

CLASSIFICATION *(V.S. Savelyev, 2015)*

➤ *By aetiology:*

- perforation of chronic ulcer
- perforation of acute ulcer (hormonal, stress-induced, etc.)

➤ *By localisation:*

- gastric ulcers (with indication of the anatomical area)
- duodenal ulcers (with indication of the anatomical area)

CLASSIFICATION *(V.S. Savelyev, 2015)*

► *By the clinical form:*

- perforation into the free abdominal cavity (typical, covered)
- atypical perforation (into the lesser sac, lesser or greater omentum – between the peritoneal laminae, into the retroperitoneal tissue, into a cavity isolated by commissures)
- combination of perforation with other complication of the ulcerative process (bleeding, stenosis, penetration, malignant degeneration)

CLASSIFICATION *(Yu.M. Pantsyrev, 1979)*

- ▶ ***By the severity of peritonitis*** (by the clinical periods):
 - ▶ stage of chemical peritonitis (primary shock period)
 - ▶ stage of development of bacterial peritonitis and syndrome of systemic inflammatory response (imaginary well-being period)
 - ▶ stage of diffuse purulent peritonitis (severe abdominal sepsis period)

Clinical course and symptoms

THREE PERIODS:

- ▶ “abdominal shock” (chemical peritonitis stage) that lasts for 6 hours on average
- ▶ “imaginary well-being” (the stage of development of serous-fibrinous peritonitis and appearance of systemic inflammatory response) – usually, hours 6 to 12
- ▶ diffuse purulent peritonitis (severe abdominal sepsis) usually appearing after 12 hours from the moment of perforation

Clinical course and symptoms

The first stage is characterised by sudden extremely *acute pain* in the epigastric region that the patients compare to a knife strike (“**knife-like pain**”) or a whip lash. The pain is initially localised in the upper parts of the abdomen, to the right from the medial line in perforation of duodenal ulcer. Quite rapidly, it spreads along the right half of the abdomen including the right iliac area and then spans all of its areas. A characteristic *irradiation of pain* to the right shoulder, supraclavicular area and the scapula is noted that depends on the irritation of the phrenic nerve endings by the spilt contents.

Clinical course and symptoms

Vomiting is not characteristic for this period (it may be observed in perforation of stenosing pyloroduodenal ulcers against the background of stretched and overfilled stomach. In such cases, the vomiting may precede the perforation). As a rule, it appears much later: in development of diffuse peritonitis

Clinical course and symptoms

- ▶ *The patient's appearance*: lying without movement on the spine or the right side, with lower extremities adducted to the abdomen while putting the arms around the abdomen (**the foetal position**), avoids changing the position
- ▶ The face is thinned, pale with scared expression and sunken eyes. Cold sweat may be present
- ▶ Frequent and superficial breathing
- ▶ *Initial bradycardia* is characteristic: the heart rate often decreases to 50-60 beats per minute
- ▶ ABP may be lowered

Clinical course and symptoms

- ▶ The tongue remains clean and wet within the first hours after perforation
- ▶ *The abdomen does not participate in breathing*
- ▶ Tension of abdominal muscles (“**board-like**” abdomen)
- ▶ In senile patients, in obesity and in exhausted subjects, the tension of anterior abdominal wall muscles may lack a pronounced character due to the sagginess of tissues

Clinical course and symptoms

- Initially, the muscular tension, as well as the pain, is localised in the upper parts of the abdomen. Gradually, it reaches the right iliac area, following the spread of gastroduodenal contents spilt into the abdominal cavity. The muscular tension is almost always maximal at the place of initial pain appearance. Simultaneously with muscular tension in the named areas, other symptoms of peritoneal irritation are detected as well.

Clinical course and symptoms

- ▶ Percussion, in a number of cases, makes it possible to reveal the presence of liquid and gas in the free abdominal cavity: the **symptom of liver dullness disappearance**
- ▶ Auscultation is of no significant importance in diagnosis of perforated ulcer

Clinical course and symptoms

Rectal examination reveals tenderness in the area of rectouterine or retrovesical pouch
(Kulenkampff symptom)

Clinical course and symptoms

Second period

- ▶ The patient's face assumes normal colour
- ▶ HR, ABP and body temperature become normal
- ▶ Breathing is freer, not superficial anymore
- ▶ The tongue becomes dry and coated
- ▶ The anterior abdominal wall is less rigid, with remaining tenderness of epigastrium and the right half of the abdomen upon palpation
- ▶ In the case of covered perforated ulcer, the pains in the upper areas of abdomen gradually disappear.
- ▶ Pains, local tension of muscles and peritoneal irritation symptoms appear in the right iliac area

Clinical course and symptoms

- ▶ In presence of a lot of free liquid in the abdominal cavity, there is dull percussion sound detectable in its gravitationally dependent areas along the right and the left lateral canals
- ▶ Peristalsis is weakened or absent
- ▶ Rectal examination may reveal overhanging of the anterior wall of the rectum and its tenderness

Clinical course and symptoms

Third period

- ▶ The patient's condition deteriorates progressively
- ▶ Vomiting repeats, dehydrating and exhausting the patient
- ▶ There is unrest in the patient's behaviour
- ▶ Skin covers and mucosae become dry
- ▶ SIRS appears: hyperthermia above 38°C, tachycardia over 90 beats per minute, arterial hypotension

Clinical course and symptoms

- Accelerated breathing reappears
- The tongue is dry, with thick coating of plaque in the form of dirty-brown crust
- Abdominal swelling appears, peristaltic sound cannot be auscultated
- A large volume of liquid is determinable in the gravity-dependent areas of the abdomen

Clinical course and symptoms

Atypical perforation

Ulcers of the cardial area of the stomach and the posterior wall of the duodenum perforate into the tissue of retroperitoneal space. In the former case, air from the stomach may enter the mediastinum, tissue of the left supraclavicular area or the left lateral wall of the chest leading to subcutaneous emphysema. In the latter case, it appears in the umbilical area and the right lumbar area

Clinical course and symptoms

Atypical perforation

Perforation of lesser curvature ulcers into the thickness of the lesser omentum leads to appearance of inflammatory infiltration and then abscess.

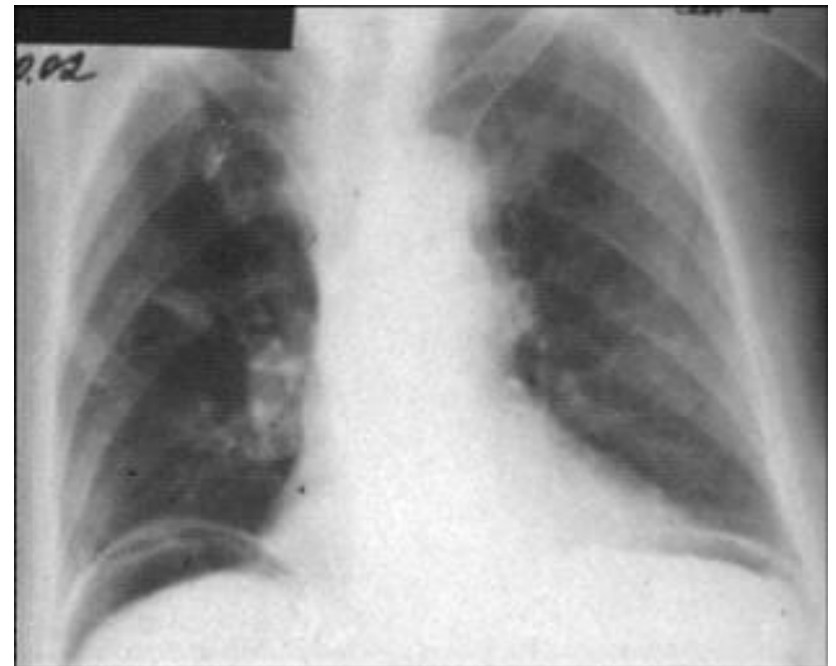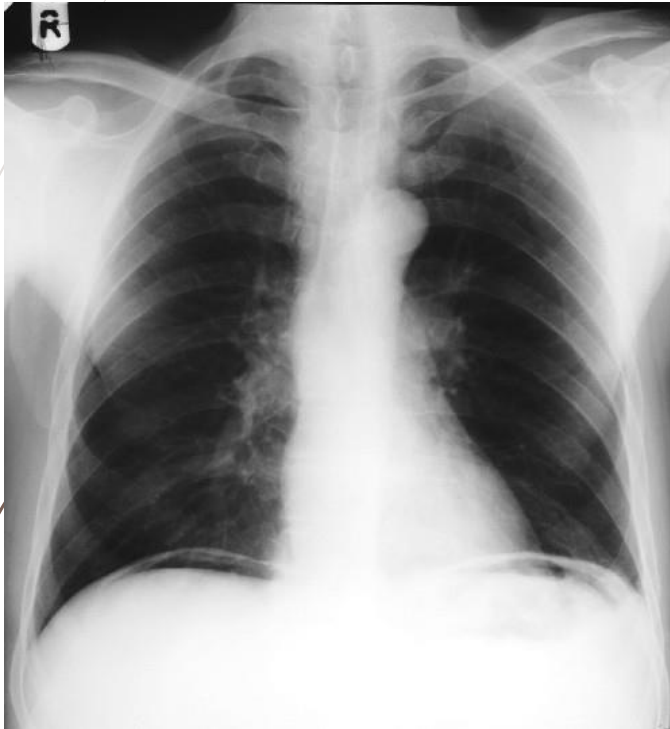
In perforation of the posterior gastric wall into the thickness of lesser or greater omentum, the abdominal pain is moderate, without clear localisation. Muscular tension of the anterior abdominal wall is not so acute. Untimely diagnosis of perforated ulcer leads to development of abscess of the lesser sac, lesser and greater omentum, retroperitoneal phlegmon, etc.

Diagnosis

IS BASED ON:

- ▶ thorough interviewing of the patient
- ▶ physical examination data
- ▶ laboratory data
- ▶ radiological data
- ▶ endoscopic methods

Radiological diagnosis



Differential diagnosis

- ▶ Tumour perforation (cachexia, tumour, bleeding, endoscopy with biopsy)
- ▶ Acute appendicitis (laparoscopy)
- ▶ Thrombosis of mesenteric vessels (MSCT-angiography, laparoscopy, rectal examination)
- ▶ Myocardial infarction (ECG)
- ▶ Acute cholecystitis (ultrasound, jaundice)

Surgical tactics and types of surgeries

Perforated ulcer is an absolute indication to urgent surgery!!!

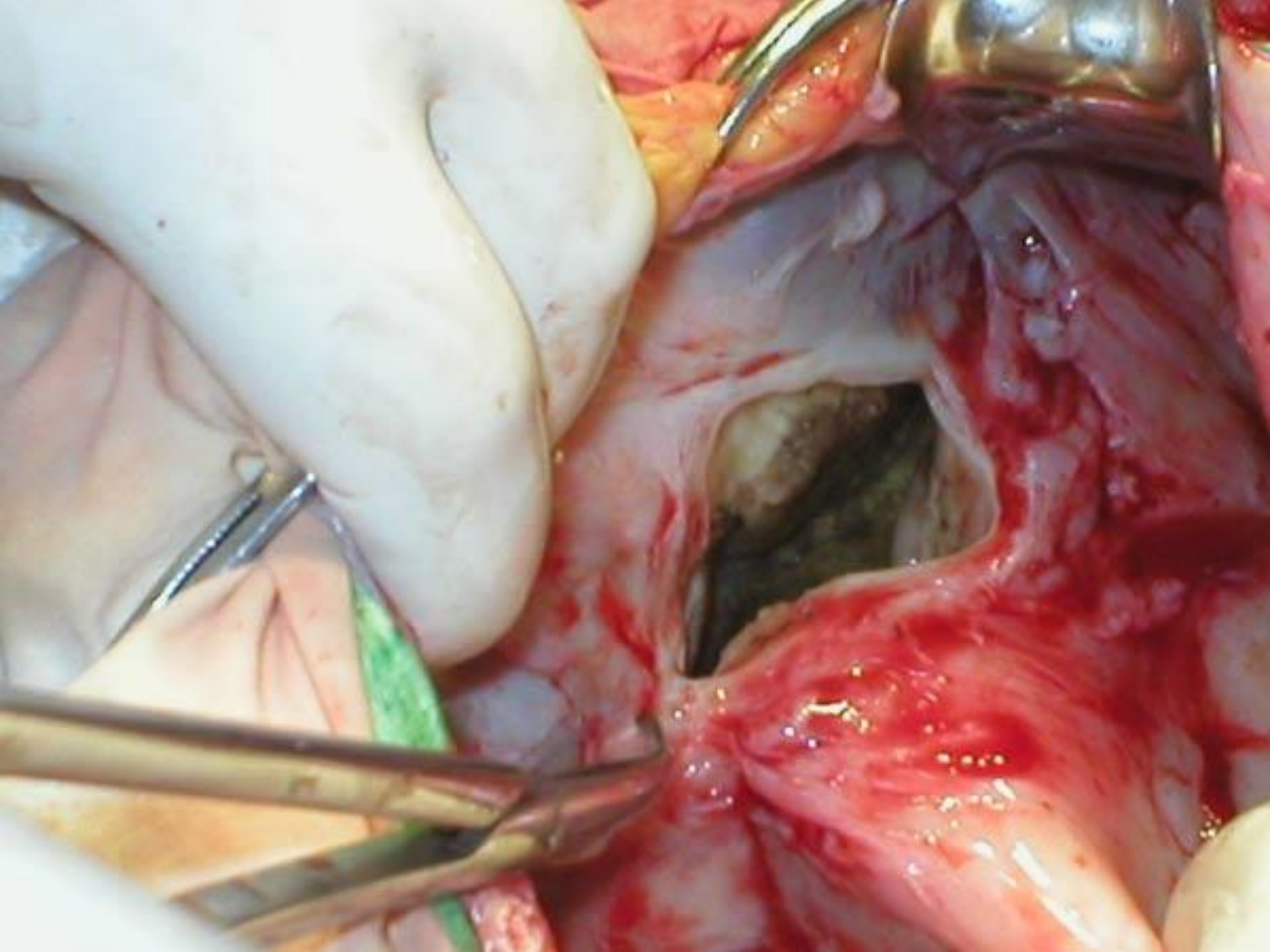
1. Suturing of ulcer
2. Excision of the ulcer with pyloroplasty combined with vagotomy
3. Gastric resection

Indications to suturing of the perforation

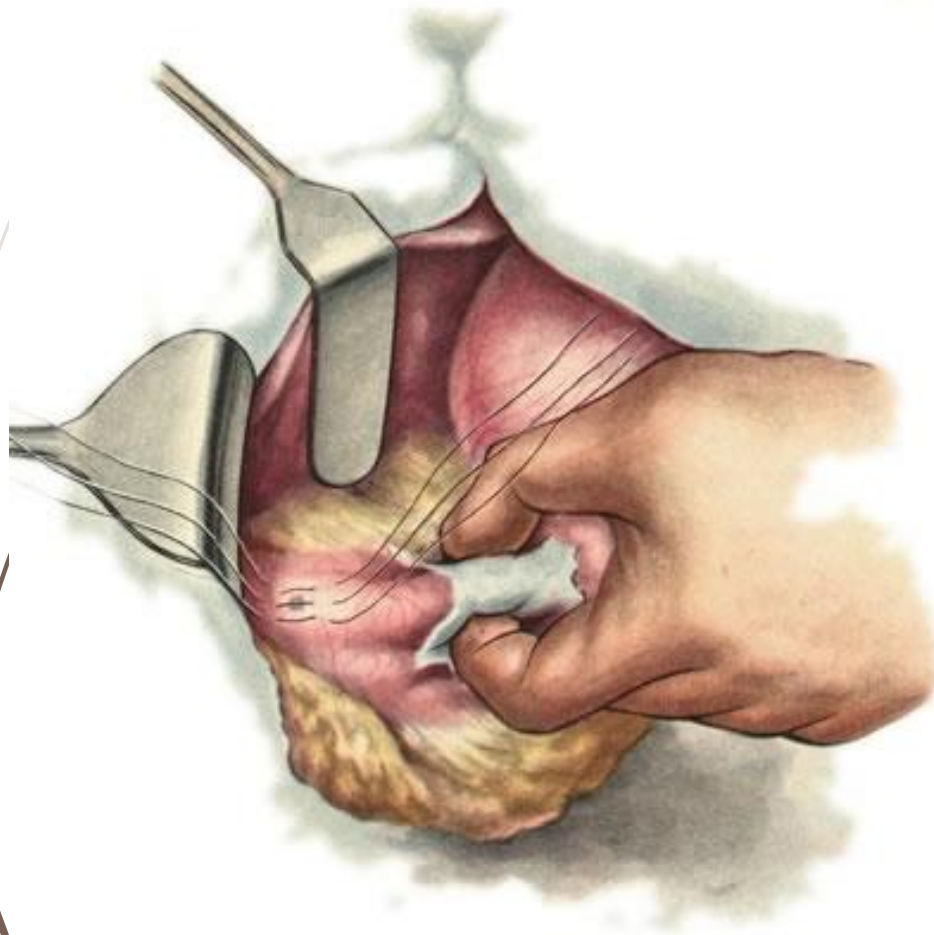
- ▶ Duration of perforation shorter than 6 hours
- ▶ Presence of diffuse peritonitis phenomena
- ▶ Presence of severe comorbidities
- ▶ Young age of the patient with “silent” or “non-treated” small ulcer with soft margins
- ▶ Low duodenal or high cardinal ulcer

Indication to gastric resection

- Large callous gastric ulcers
- Suspected malignant degeneration
- Malignant degeneration, repeated perforation
- Impossibility of suturing the perforation orifice
- Combination of perforation with bleeding

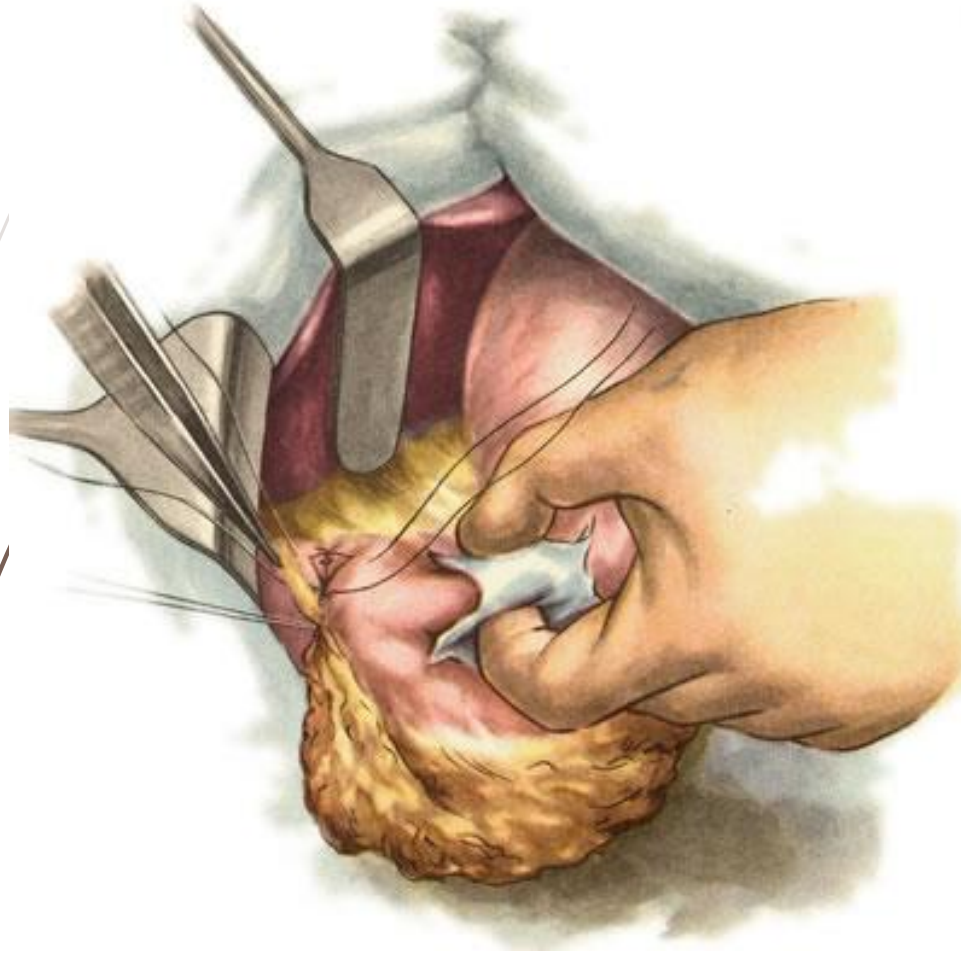


Suturing of perforated gastric ulcer



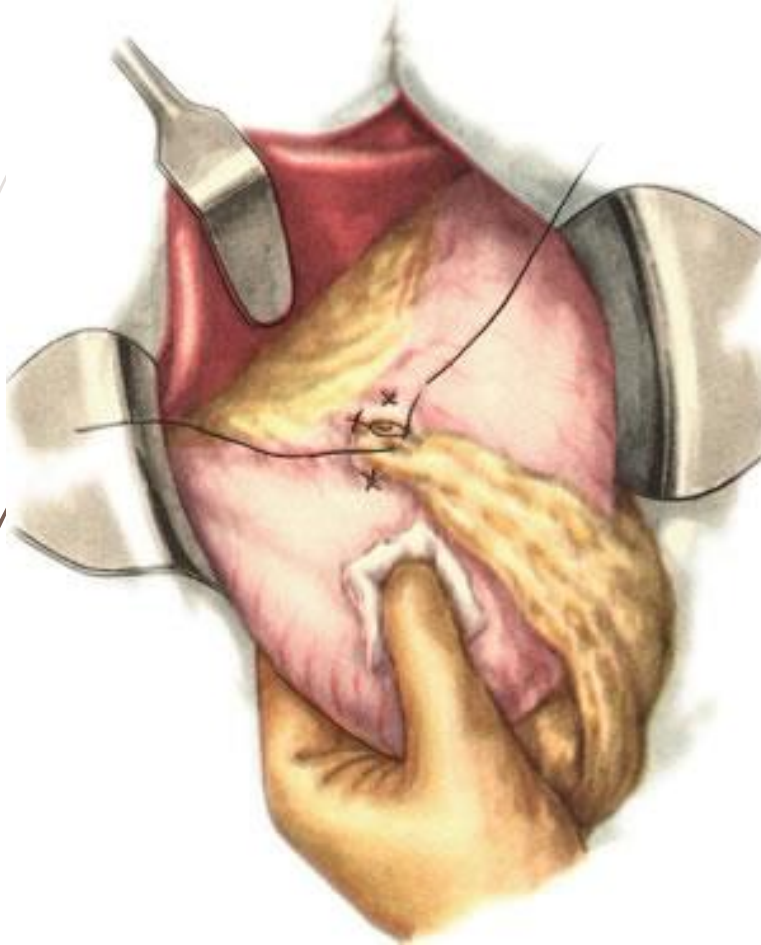
Application of
interrupted
seromuscular stitches

Suturing of perforated gastric ulcer



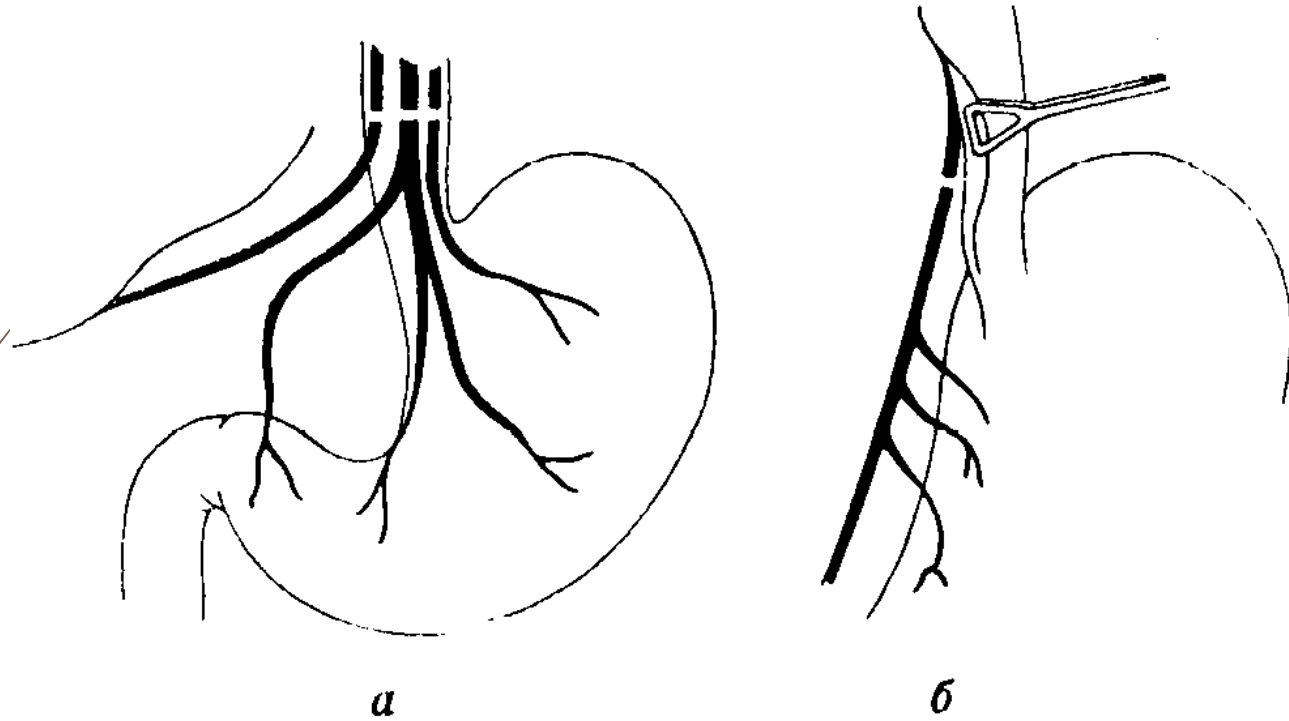
Application of the second row of seromuscular stitches and tying of omentum with a pedicle

Suturing of perforated gastric ulcer



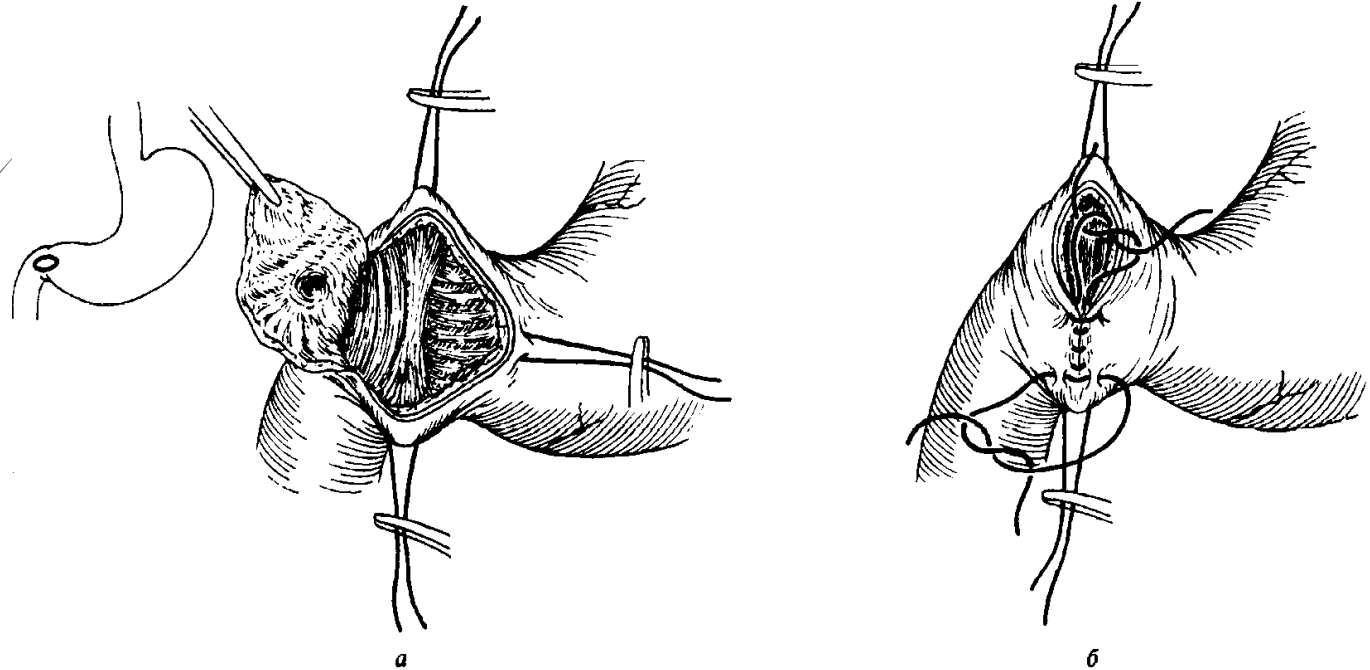
Tamponade of perforated gastric ulcer using omentum with a pedicle

Stem vagotomy



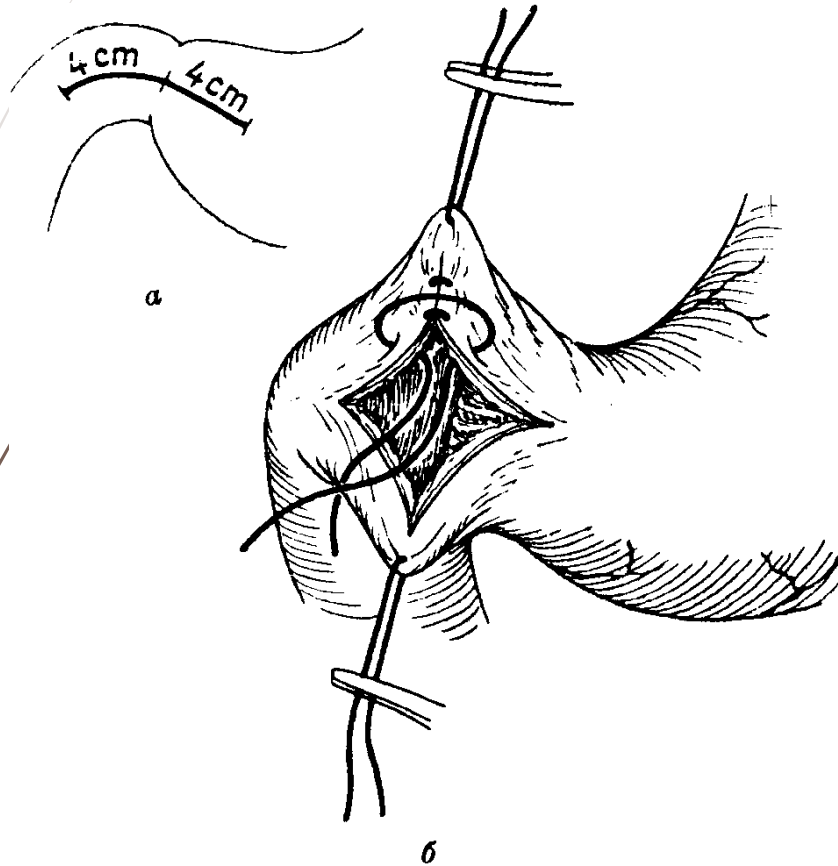
Dissection of the anterior (left) vagus nerve (*a*)
and posterior (right) vagus nerve (*b*)

Gastric ulcer excision



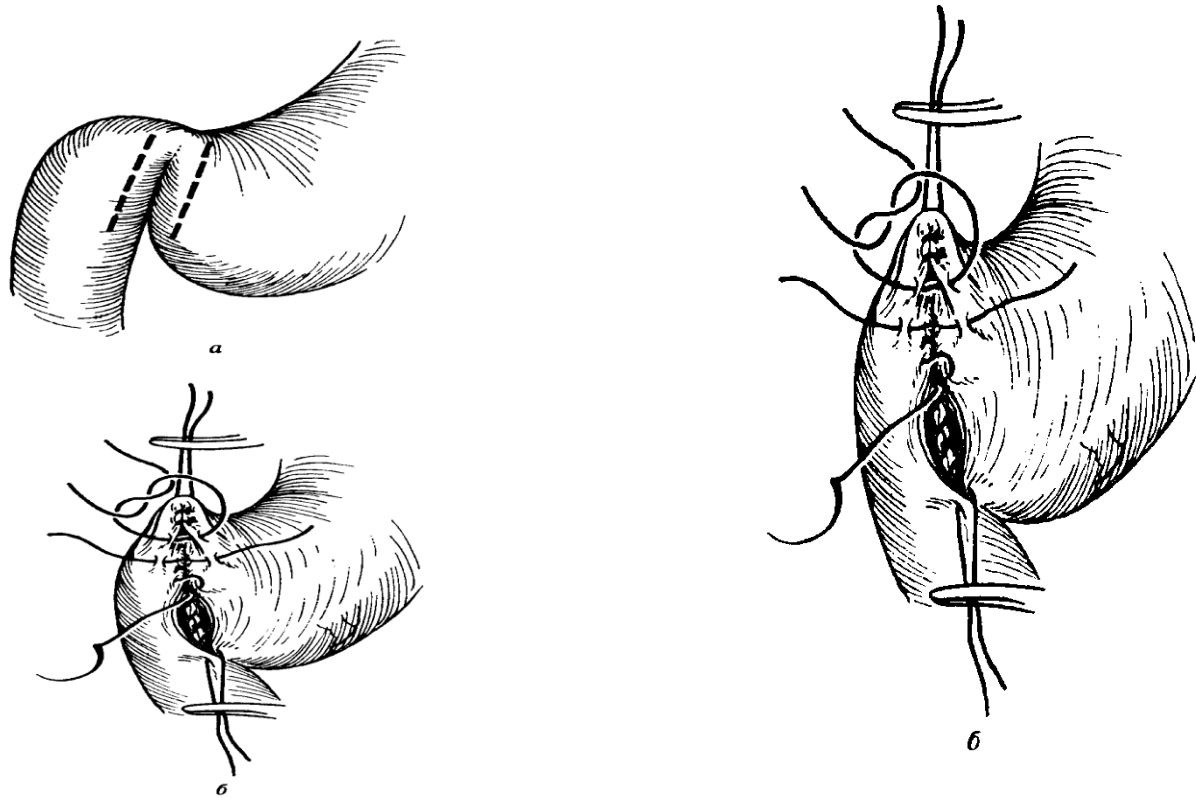
Excision in perforated gastric ulcer (a)
and pyloroplasty (b)

Heineke-Mikulicz pyloroplasty



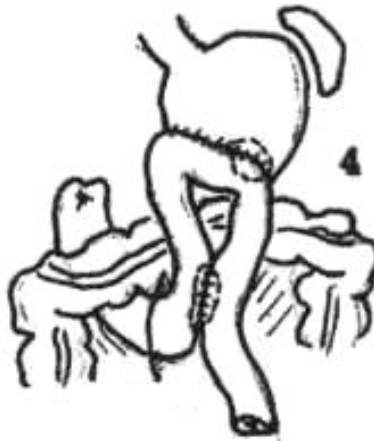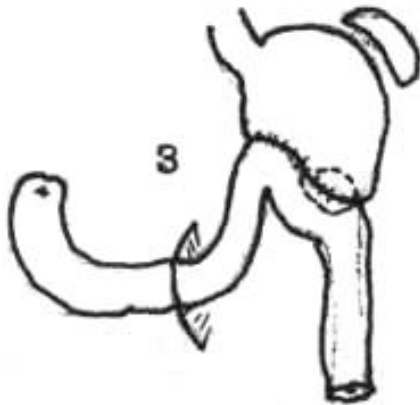
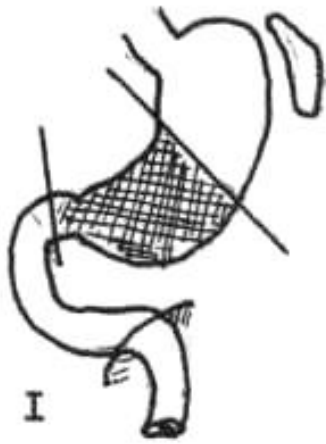Longitudinal incision (a)
and transverse suturing (b)

Jabouley pyloroplasty



Incision on the stomach and duodenum (*a*) и and gastroduodenostomy (*b*)

Modifications of Billroth II gastric resection



- 1 - resection of 2/3 of the stomach
- 2 - Roux surgery
- 3 - Hofmeister-Finsterer operation
- 4 - Balfour's method

QUESTION

What are indications to urgent surgery in gastroduodenal ulcerative bleeding?



THANK YOU FOR ATTENTION!