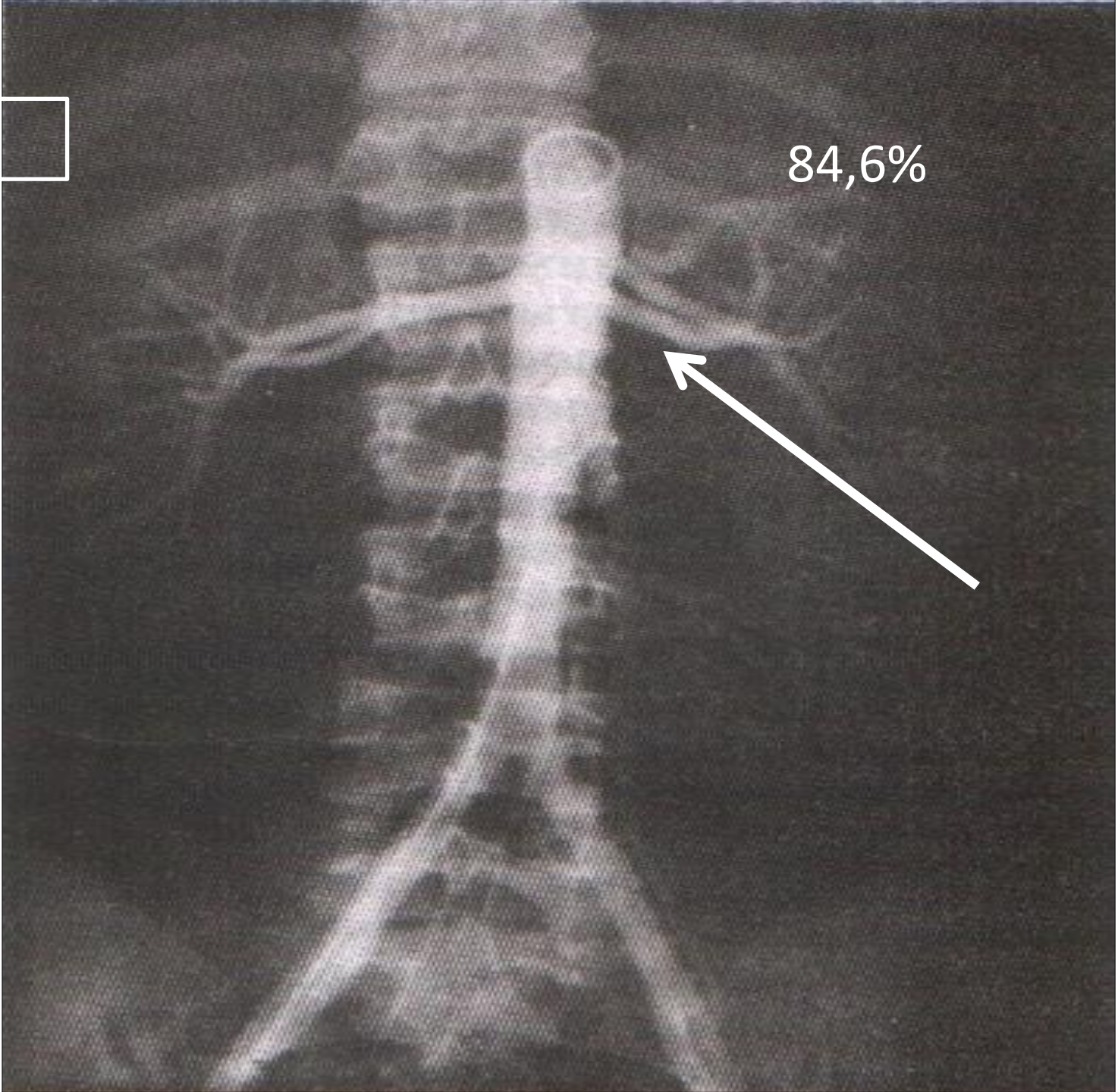



АНОМАЛИЯ РАЗВИТИЯ МОЧЕПОЛОВОЙ СИСТЕМЫ

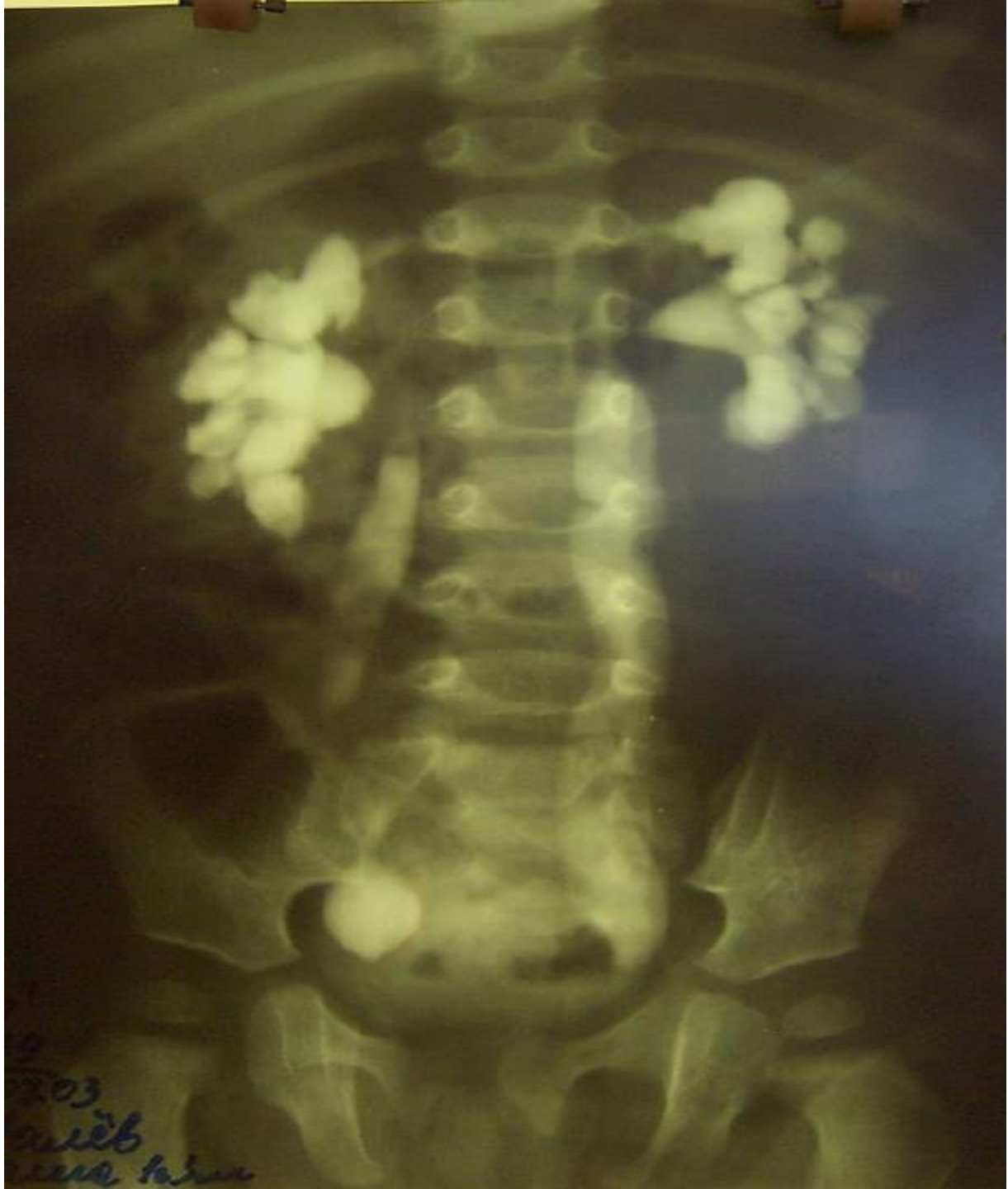1



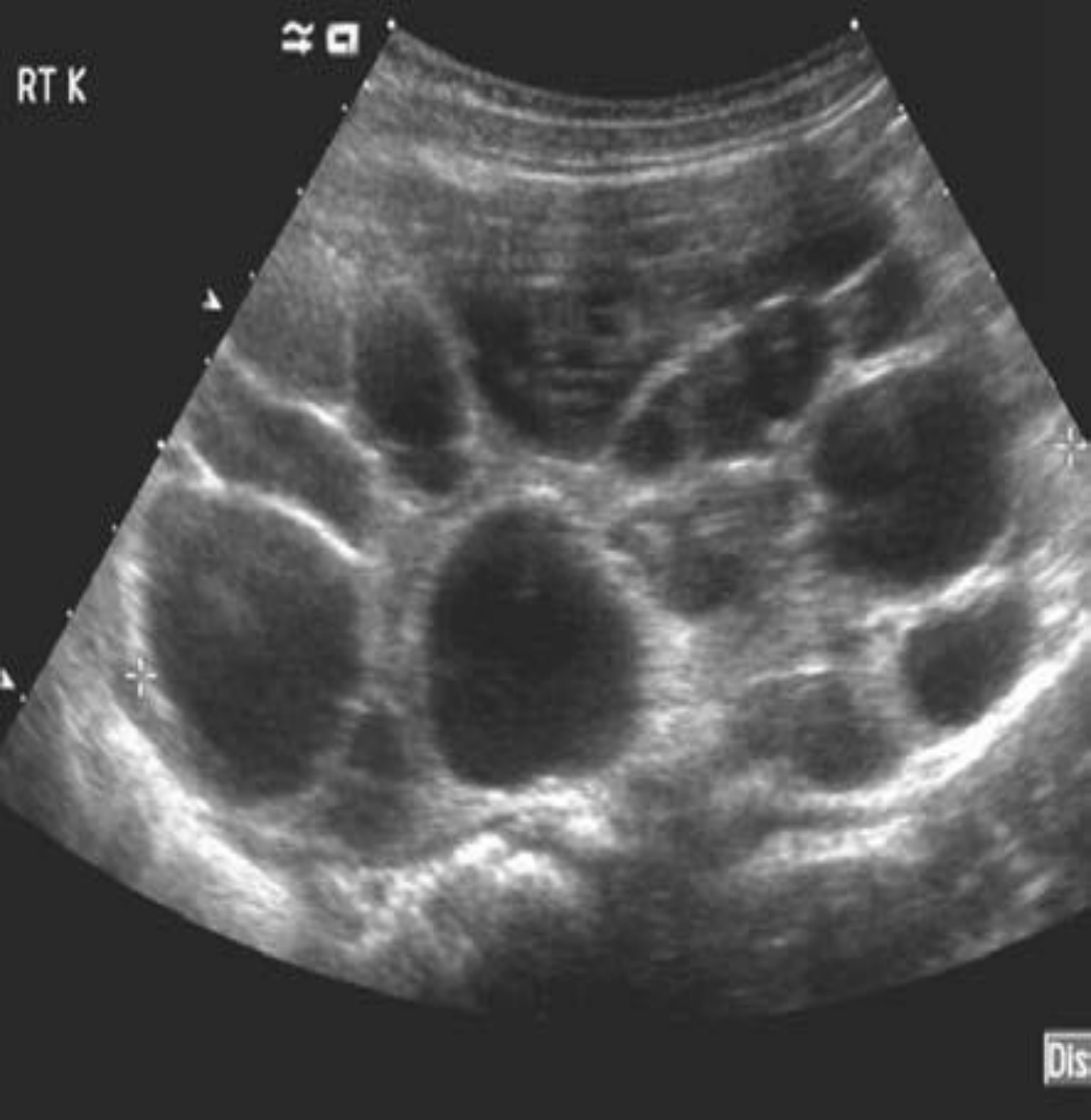
84,6%




2

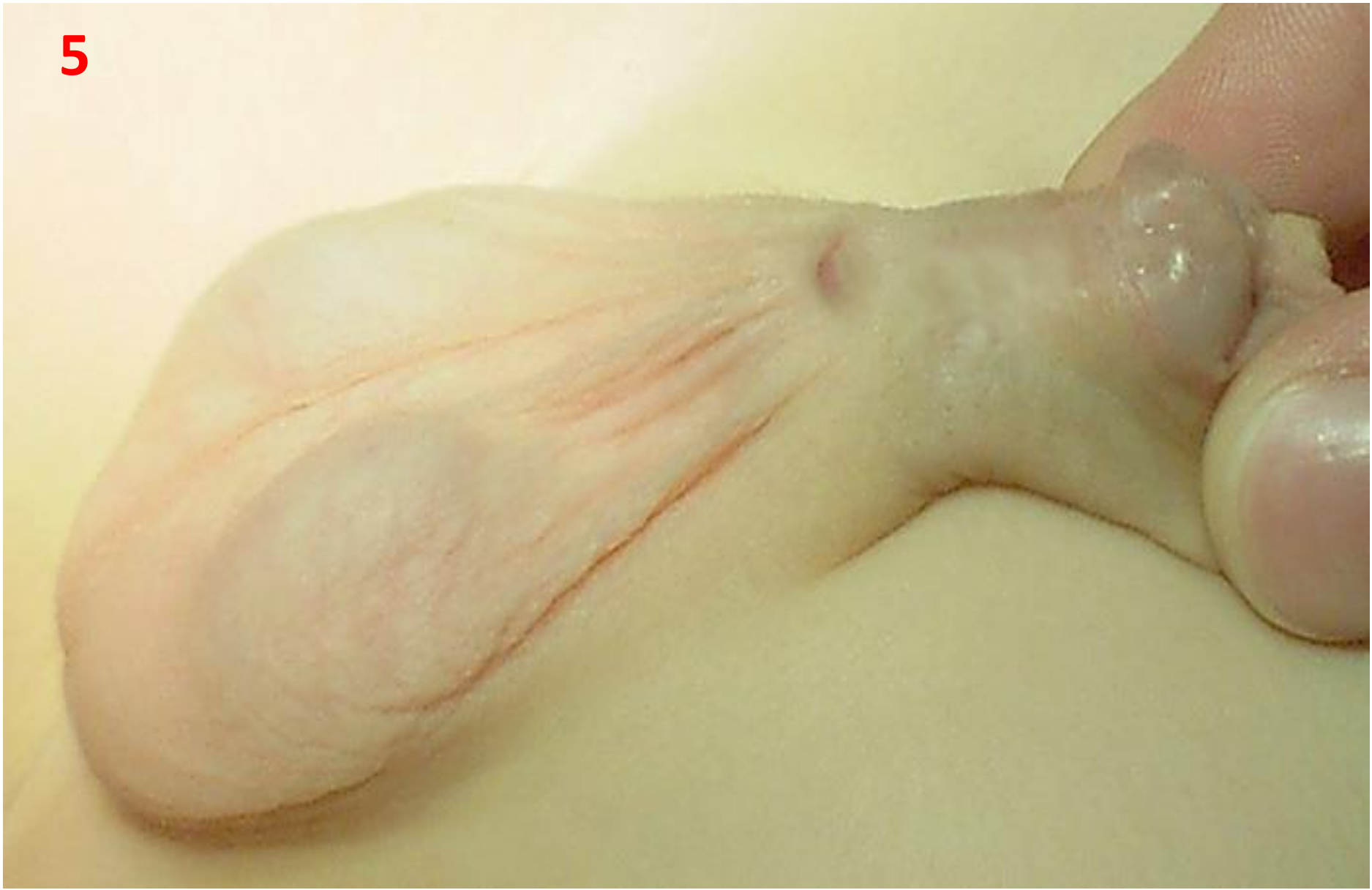

3

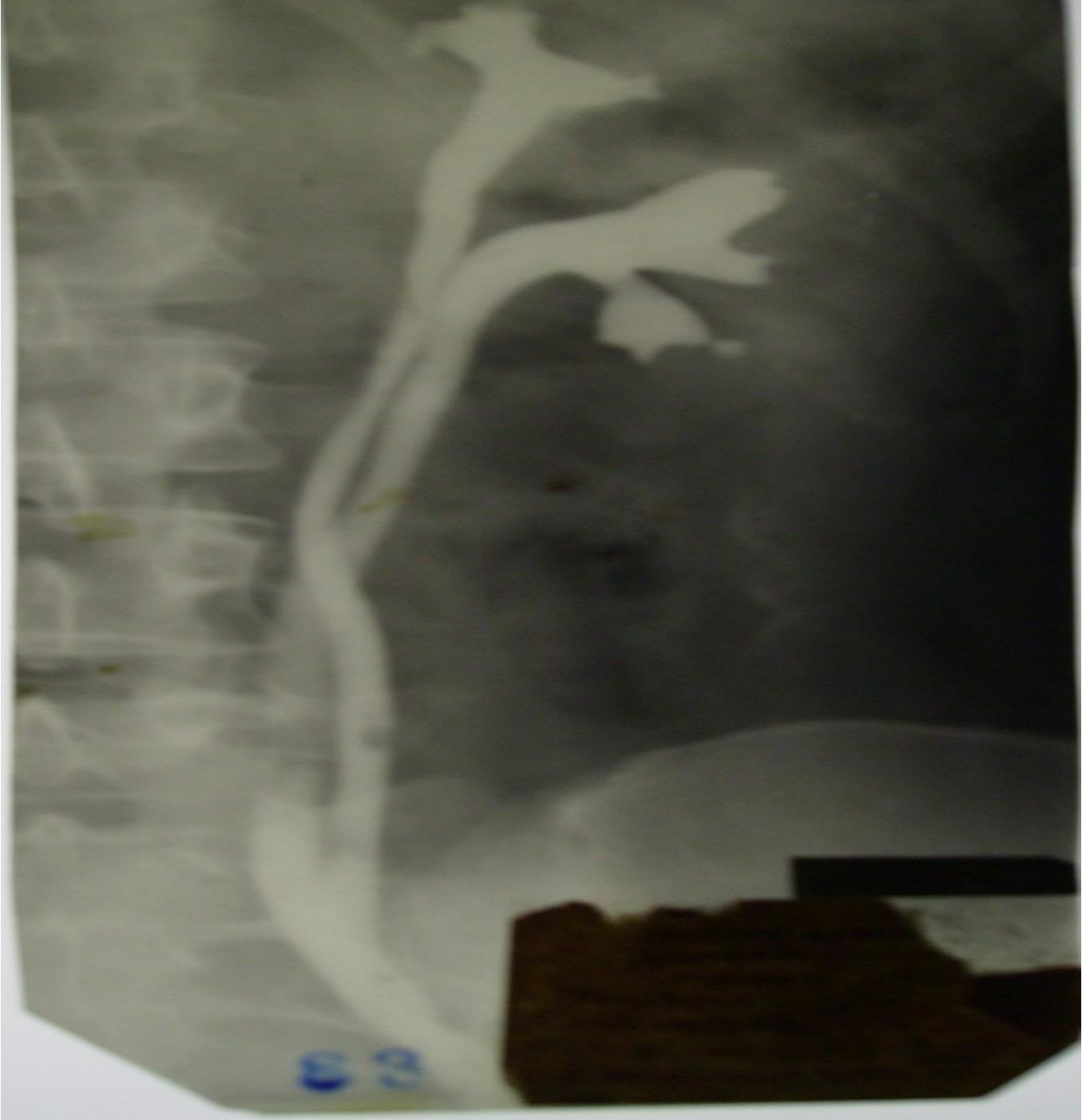




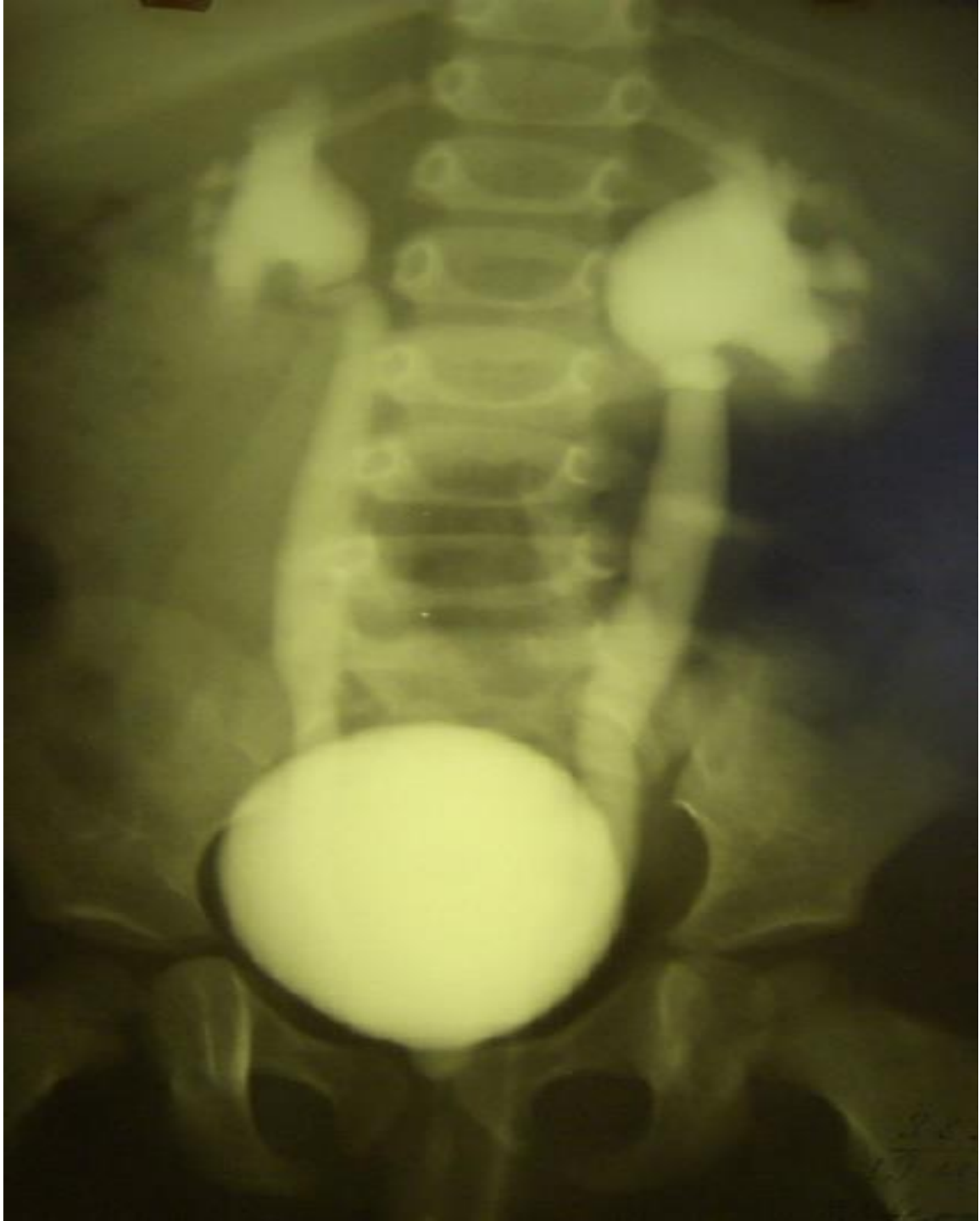
5



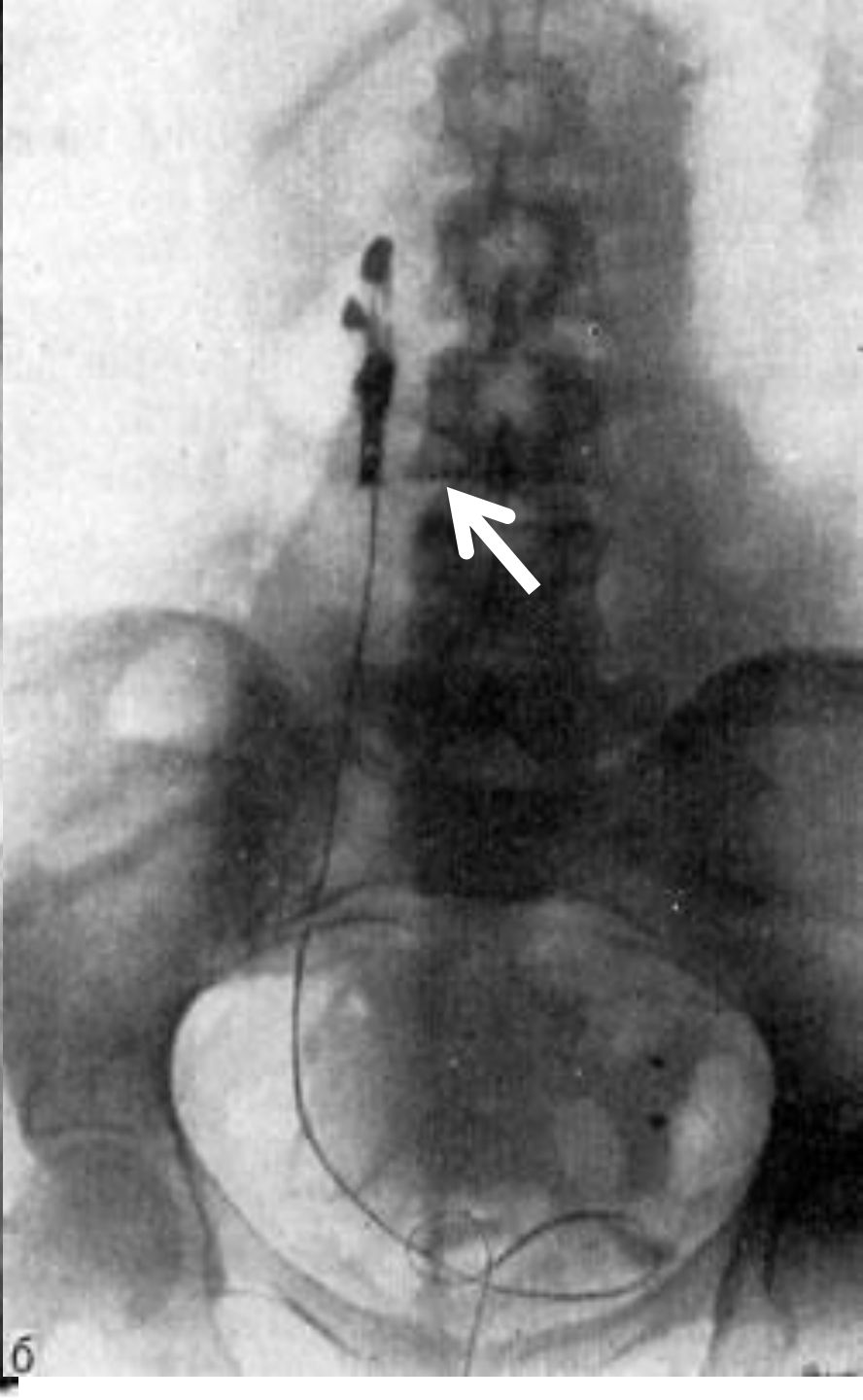
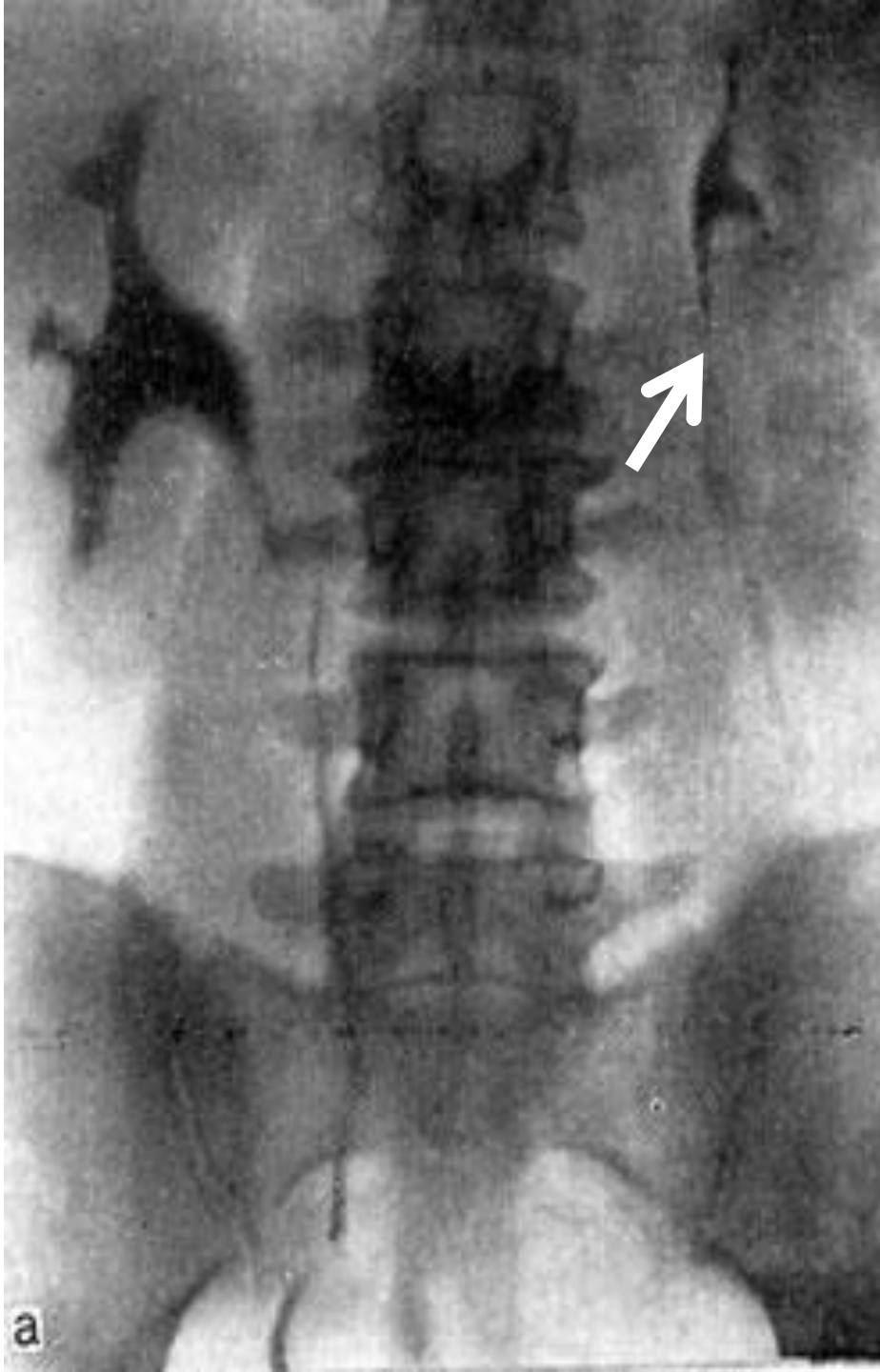6



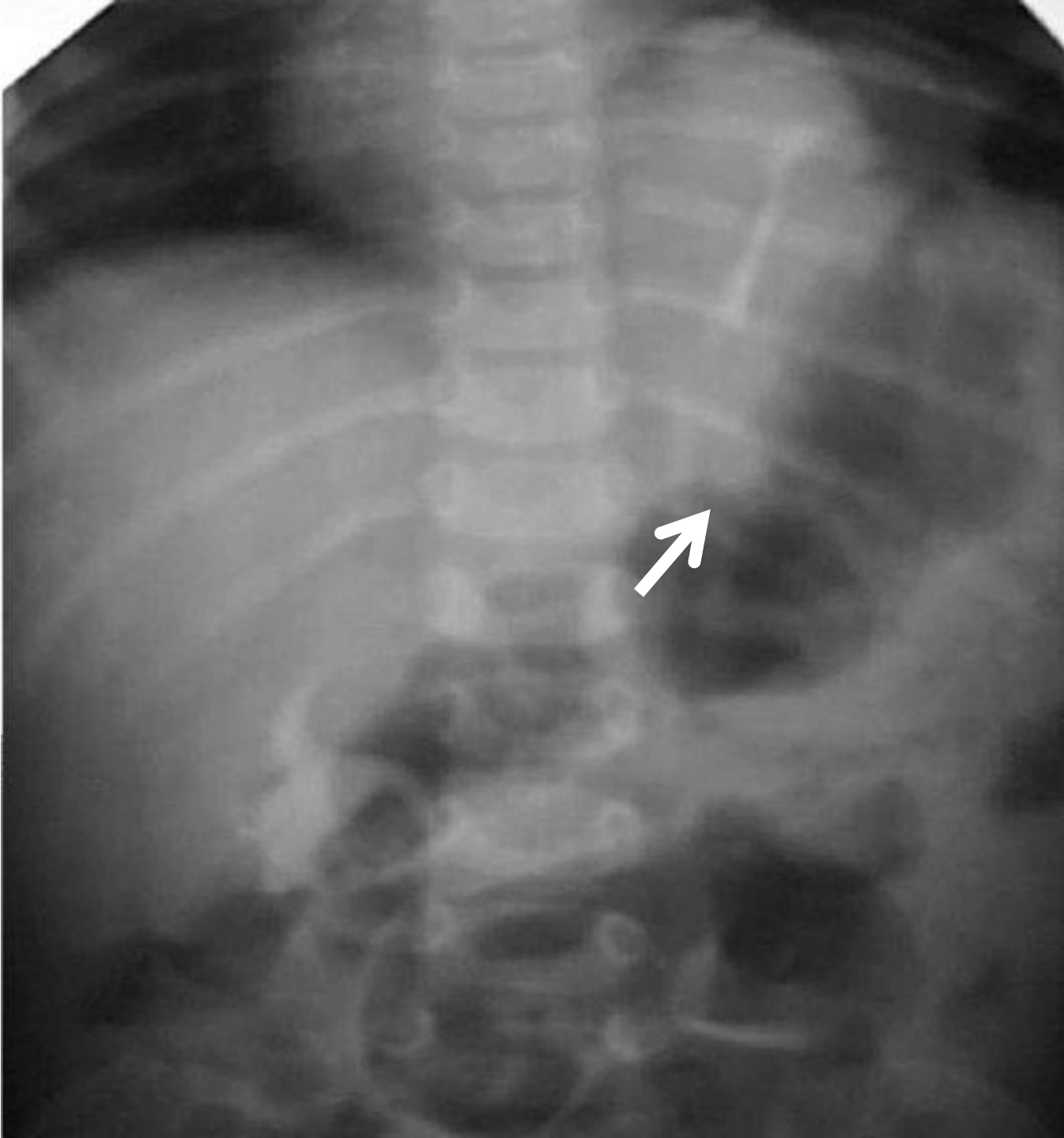7



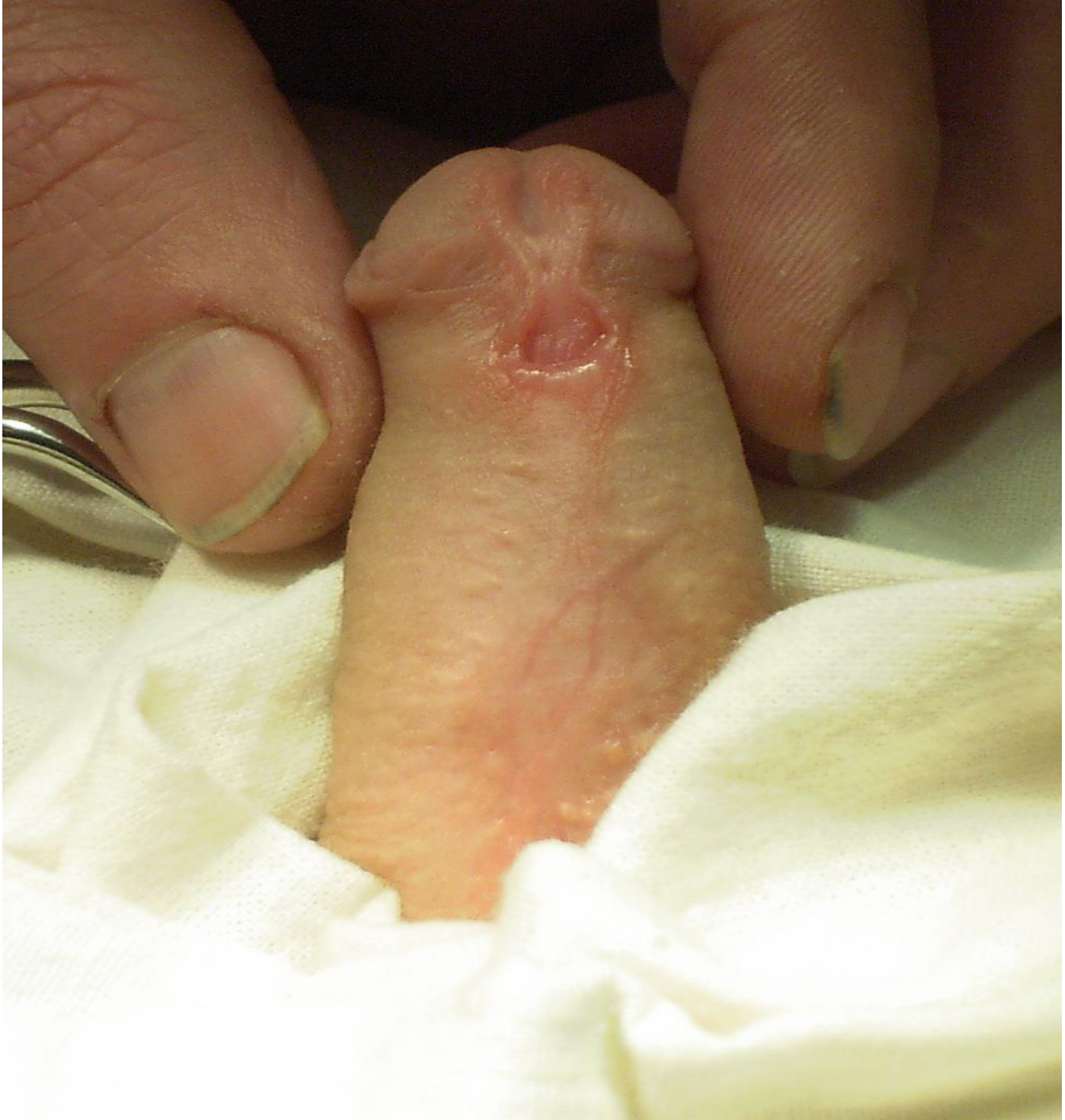8



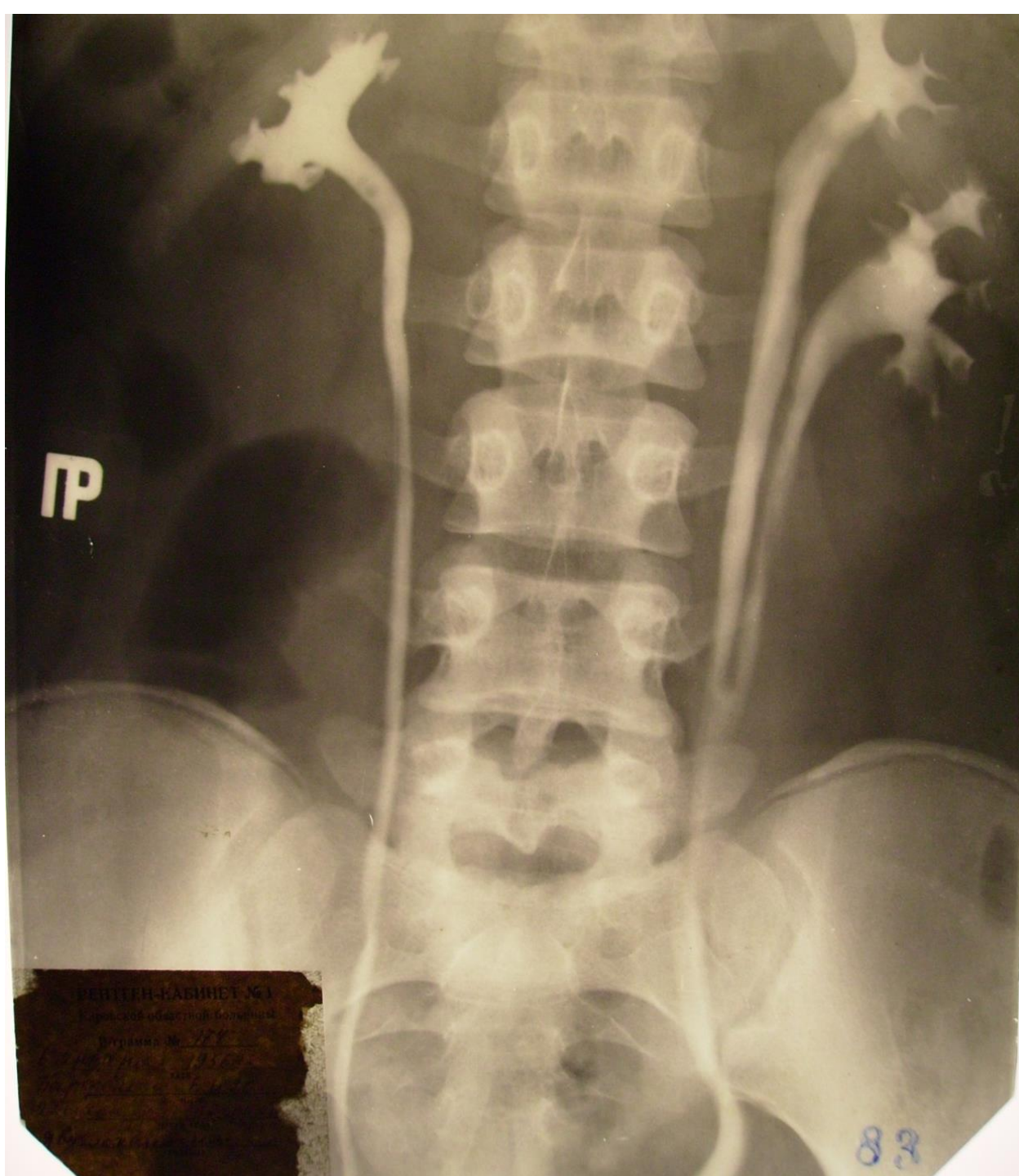9



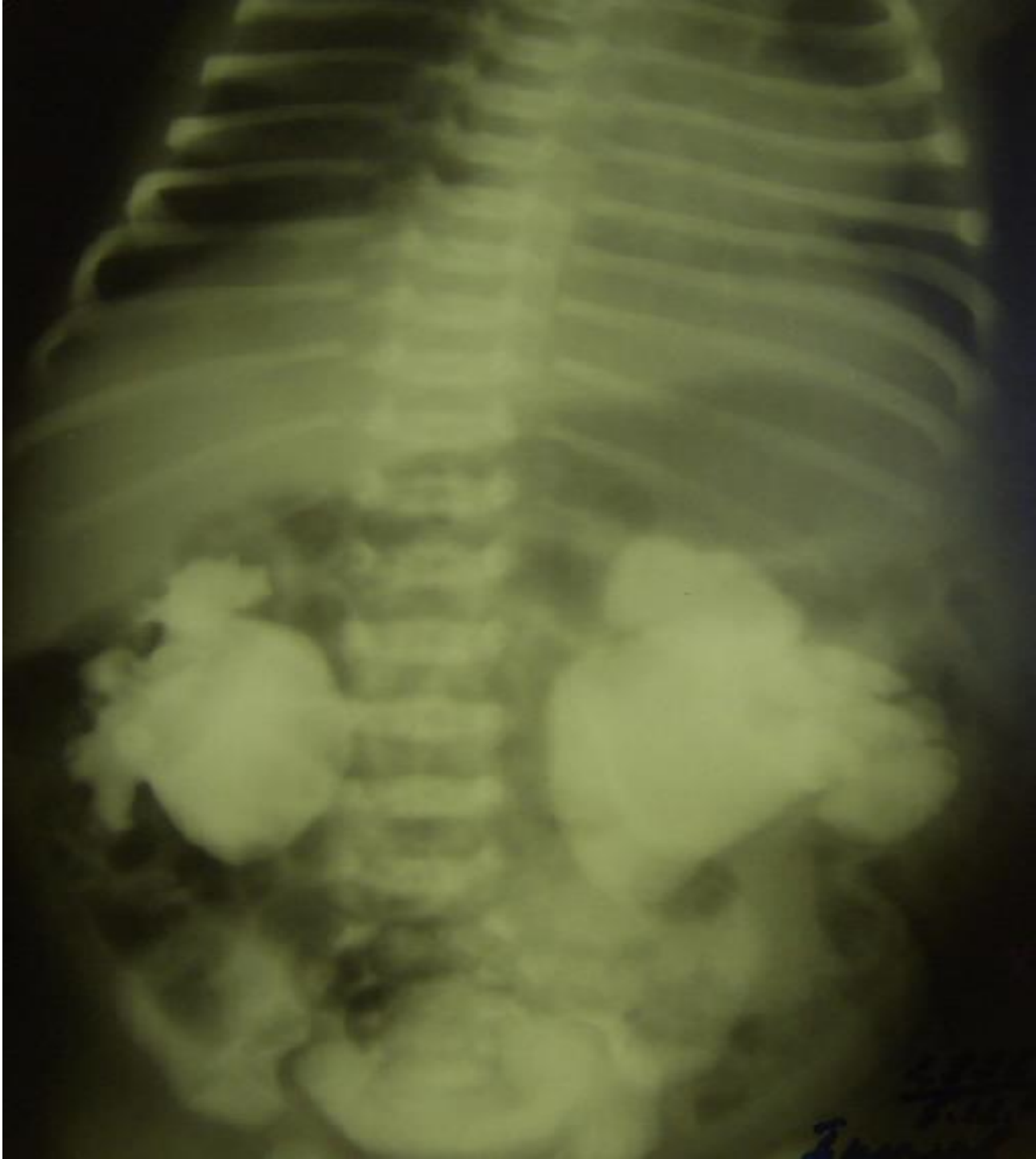10



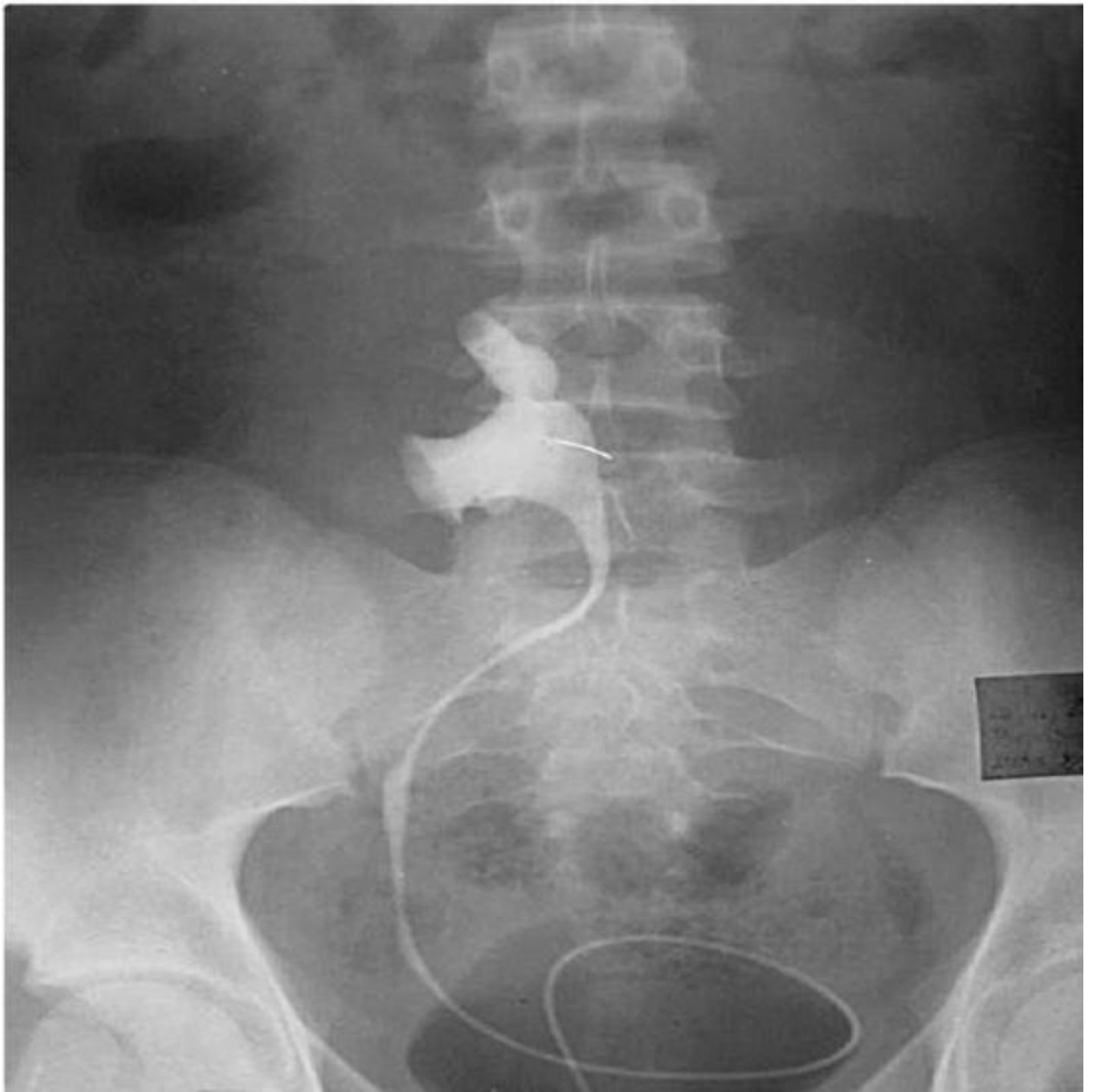11

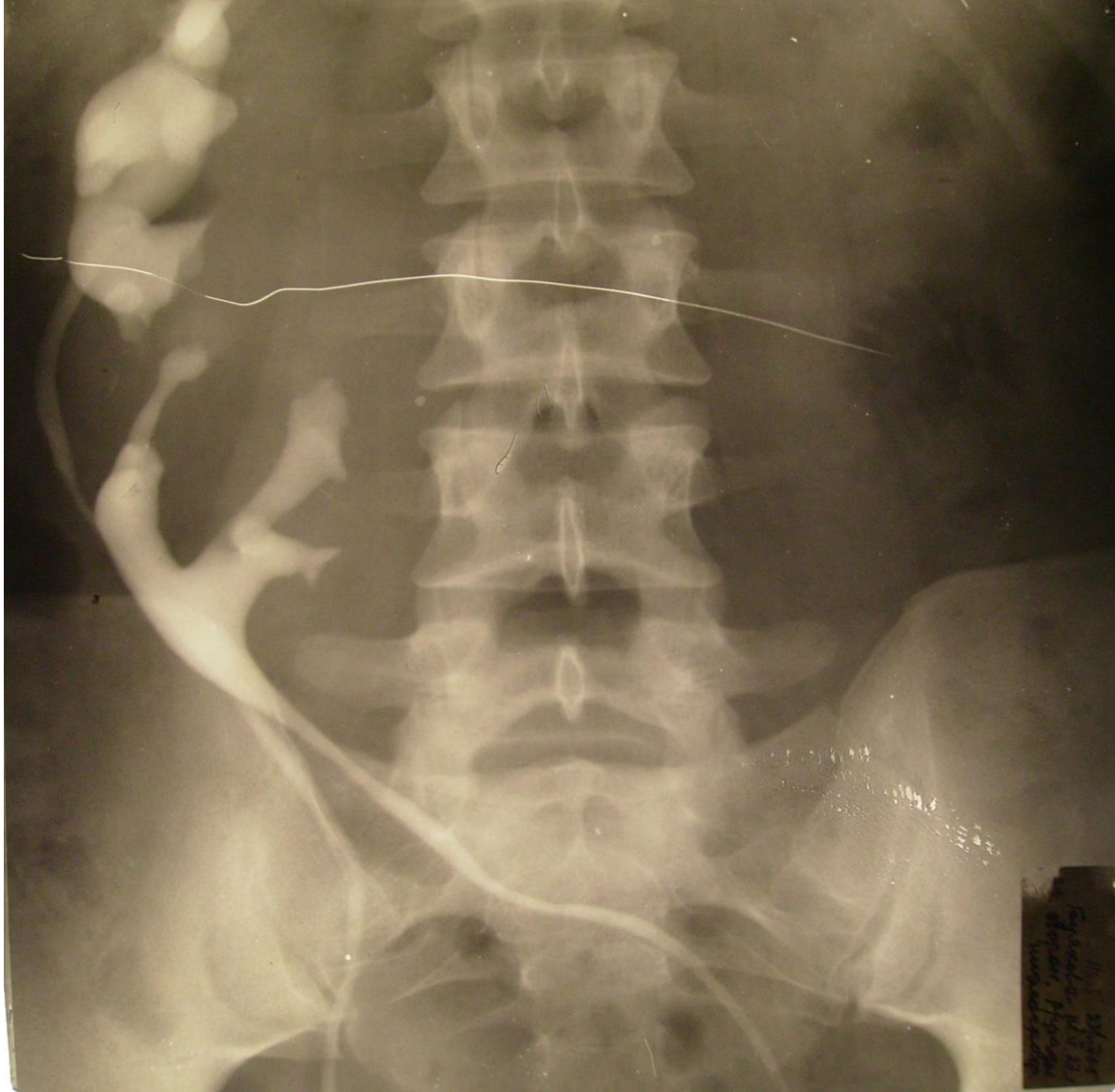

12



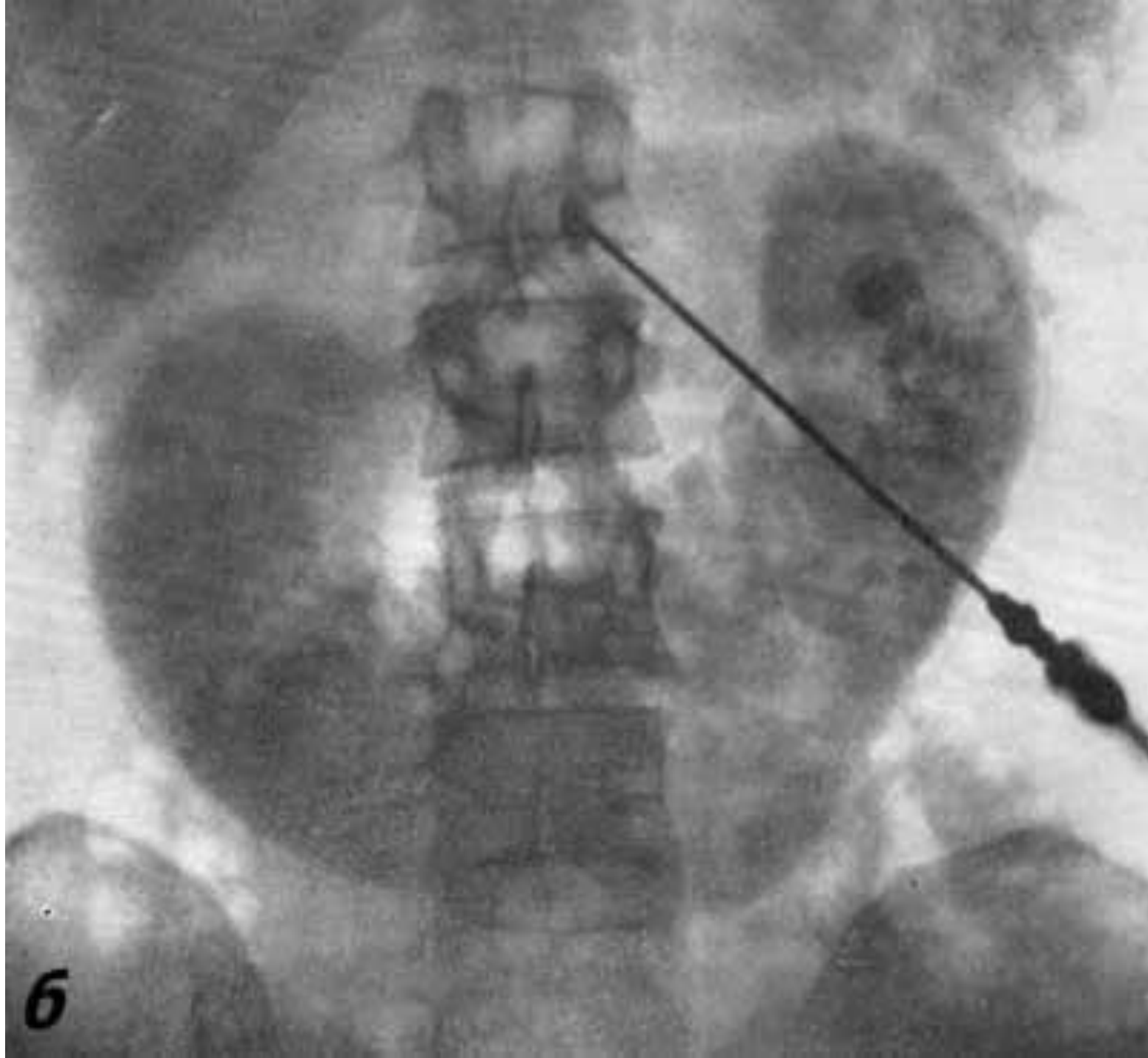
13





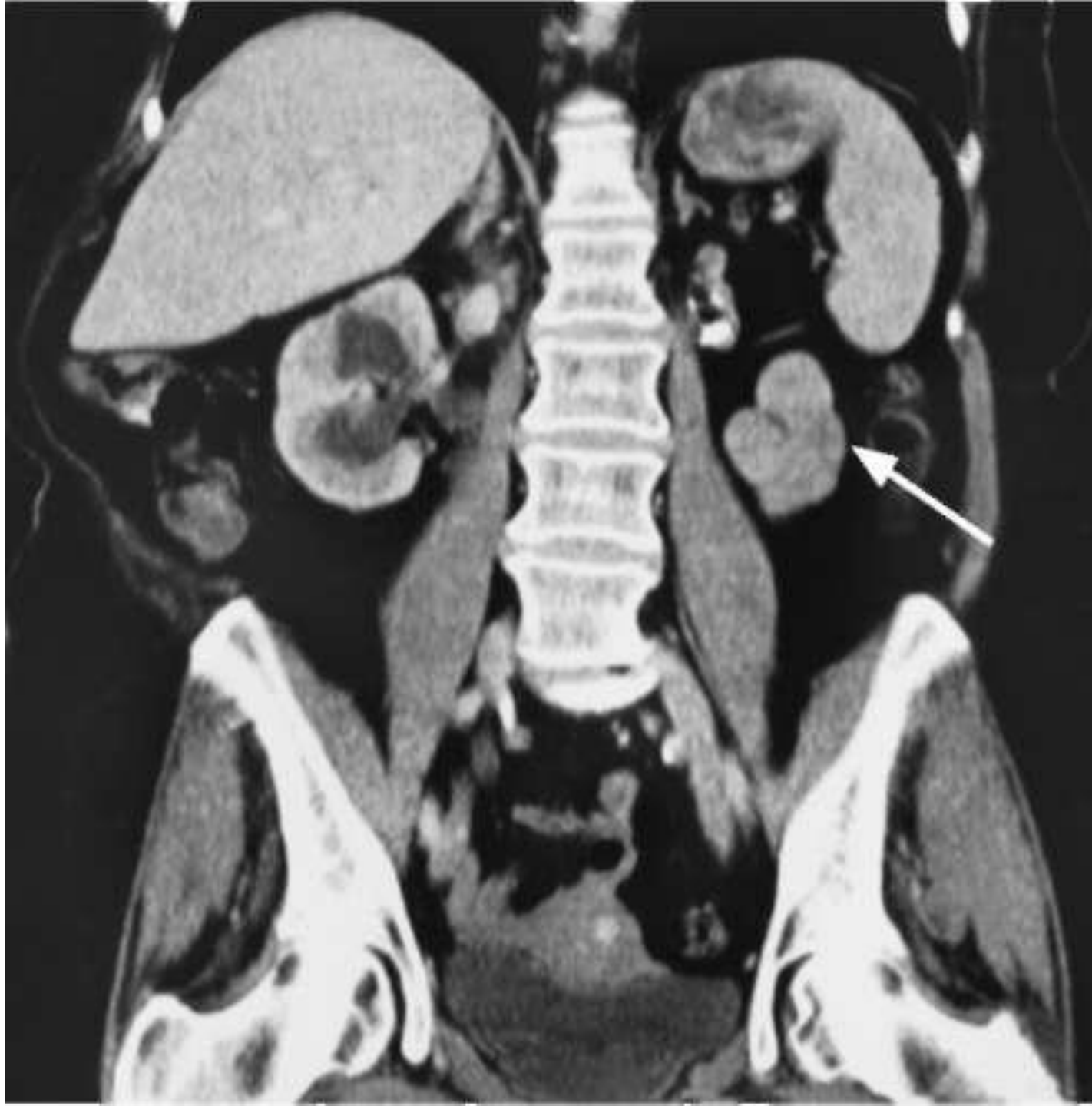AP Lumbar Spine
L5 vertebral body lesion
10/10/10
10/10/10

15

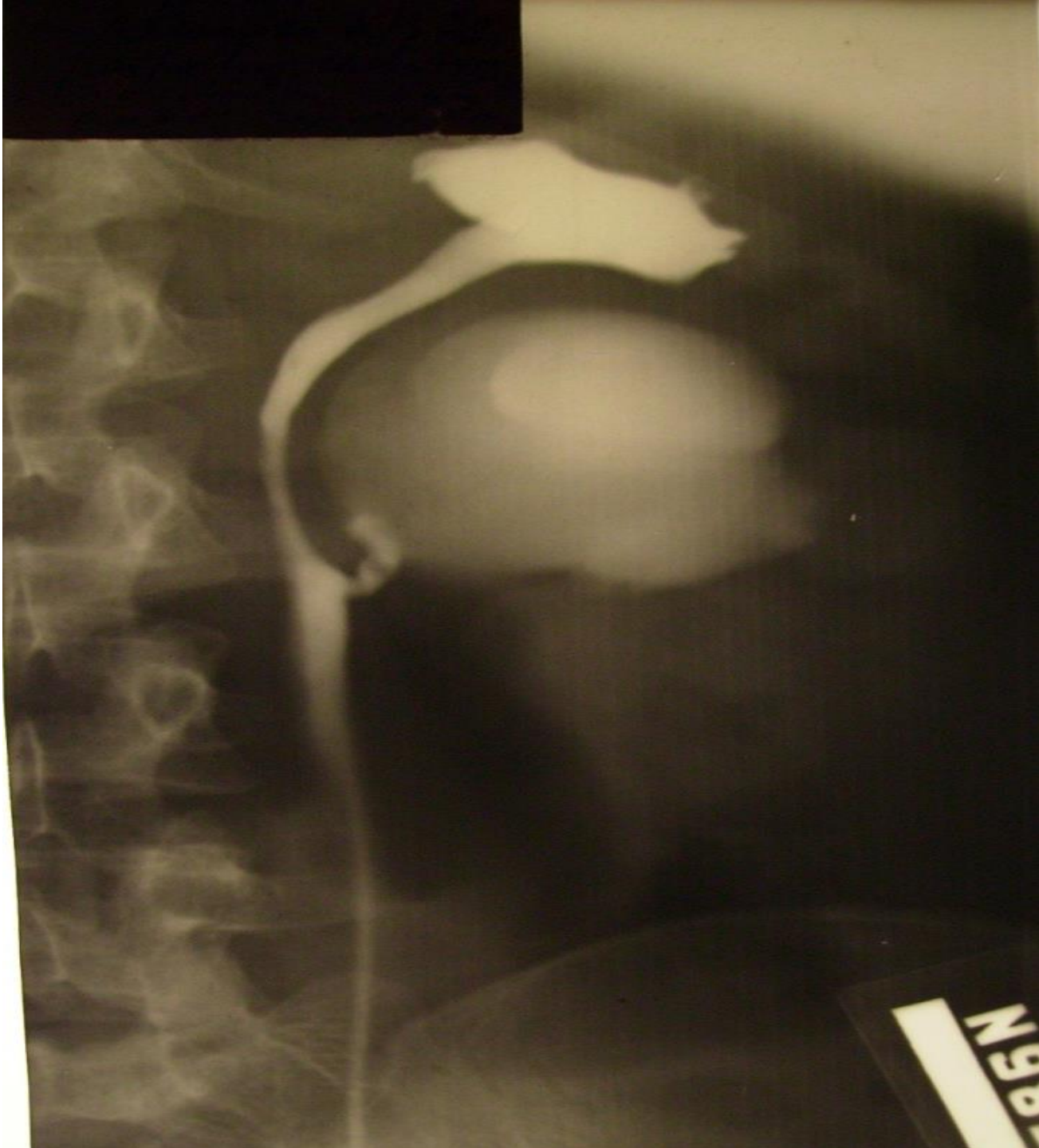

6

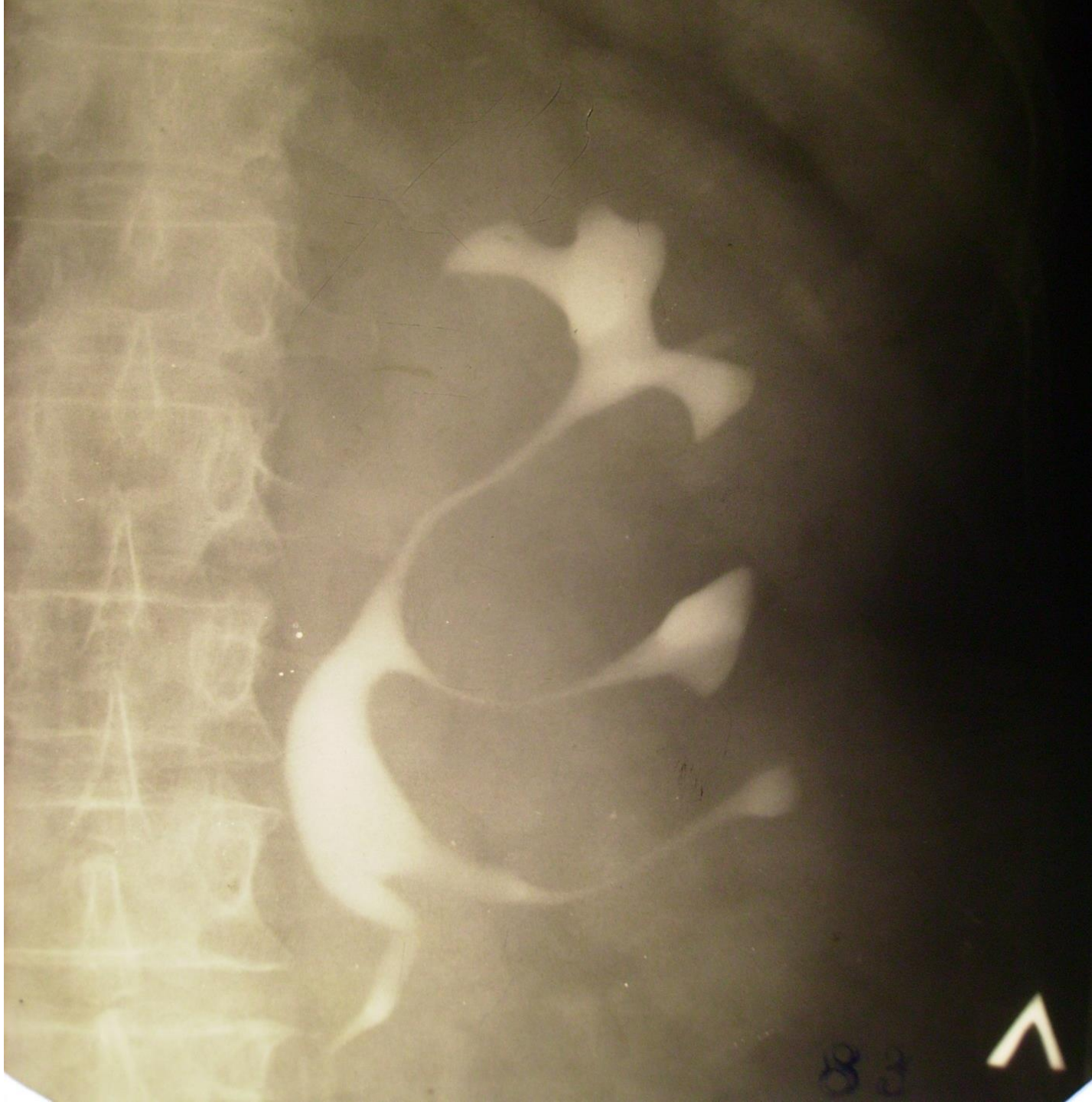16



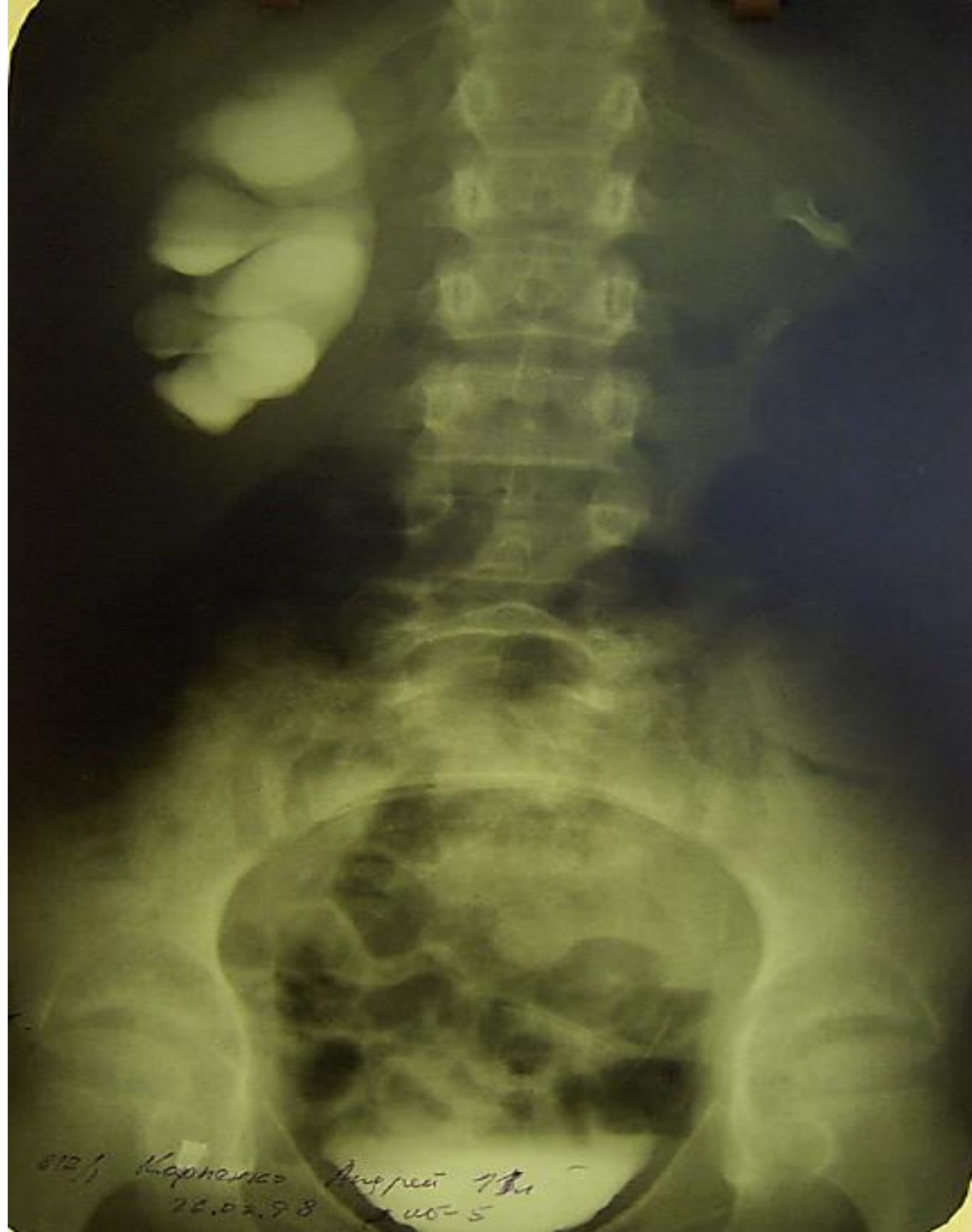17



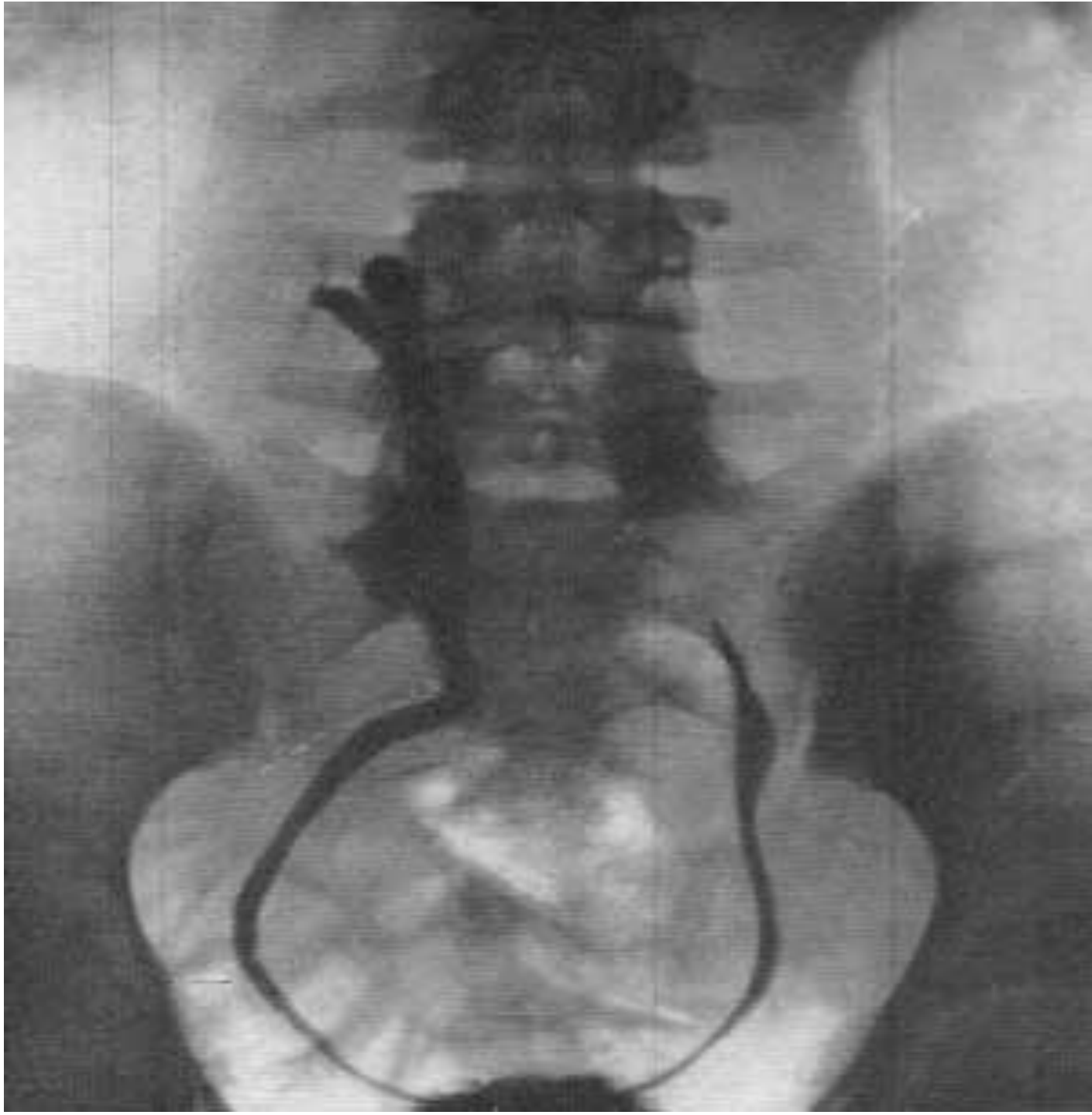18



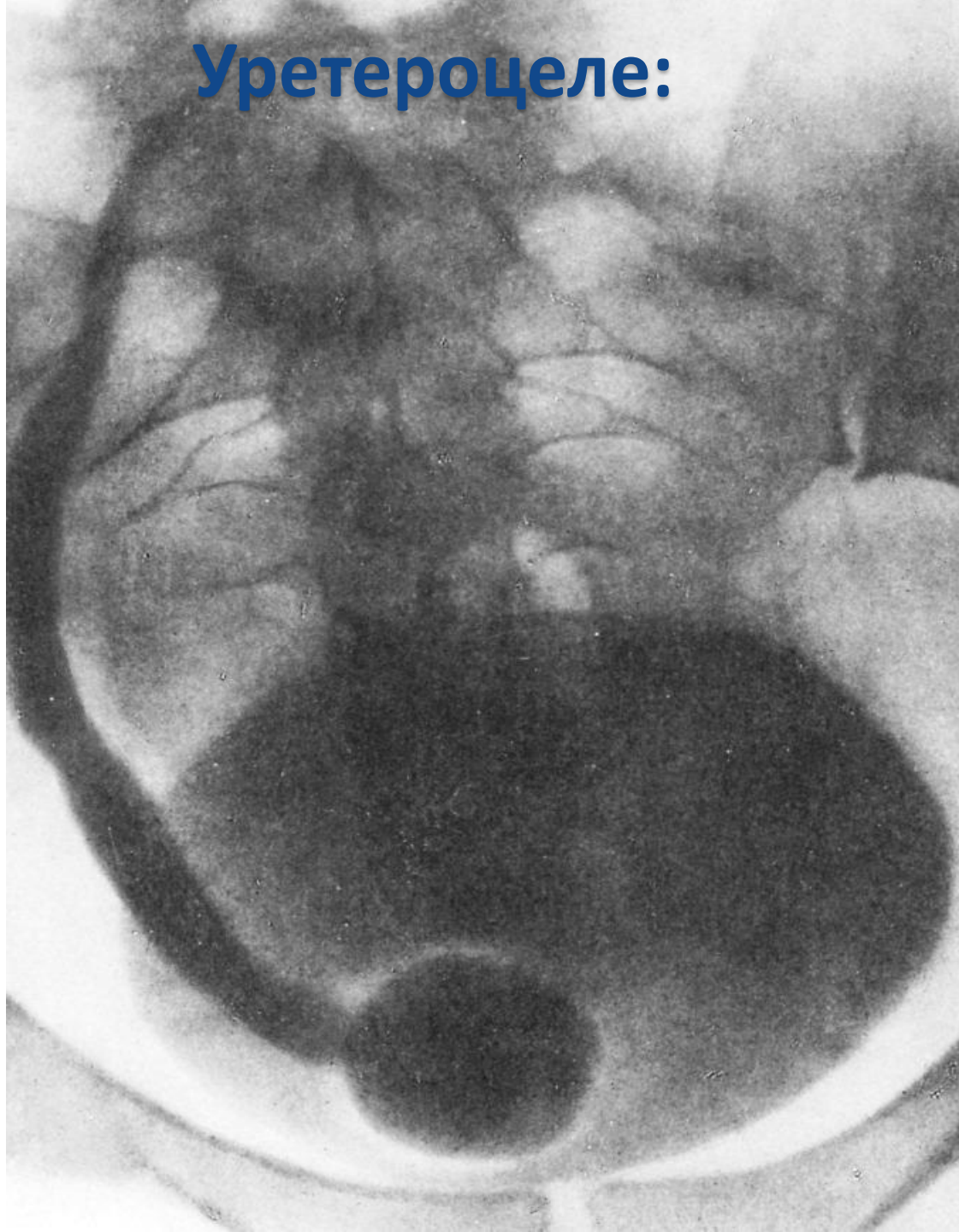19



20



Уретероцеле:



S-образная и L-образная почки

