КРАСНОЯРСКИЙ МЕДИЦИНСКИЙ УНИВЕРСИТЕТ
1942/2022

Federal State Budgetary Educational Institution
of Higher Education Professor V.F. Voyno-Yasenetsky
Krasnoyarsk State Medical
University of the Russian Federation
Department of Operative Surgery and
Topographic Anatomy

Surgical interventions on blood vessels, nerves, tendons

Lecture plan

1. The history of vascular surgery.
2. General provisions when performing vascular operations:

a) Vascular and nerve syntopia (vascular projection lines);

b) Acute and chronic blood flow disorders – collaterals;

c) Components of effective collateral circulation;

d) Special vascular instruments;

e) Ligation of large vessels.

3. Operations on vessels:

a) Operations that restore the potency of vessels;

b) Operations that eliminate the lumen of vessels;

c) Palliative surgery.

План лекции

1.История развития хирургии сосудов.
2.Общие положения при выполнении операций на сосудах:
а) синтопия сосудов и нервов (проекционные линии сосудов);
б) острое и хроническое нарушение кровотока – коллатерали;
в) слагающие эффективного коллатерального кровообращения;
г) особые сосудистые инструменты;
д) перевязка крупных сосудов.
3. Операции на сосудах:
а) операции, восстанавливающие проходимость сосудов;
б) операции, ликвидирующие просвет сосудов;
в) паллиативные операции

Purpose:

- To give a topographic and anatomical justification of the basic principles of surgical interventions on vessels

Цель:

- Дать топографо-анатомическое обоснование основным принципам оперативных вмешательств на сосудах

History of vascular surgery
История хирургии сосудов

330-250 BC Erasistratus
330-250 гг. до н.э. Эразистрат

Applying ligatures to vessels.
наложение лигатур на сосуды.

120-210 Galen
120-210 гг. Гален

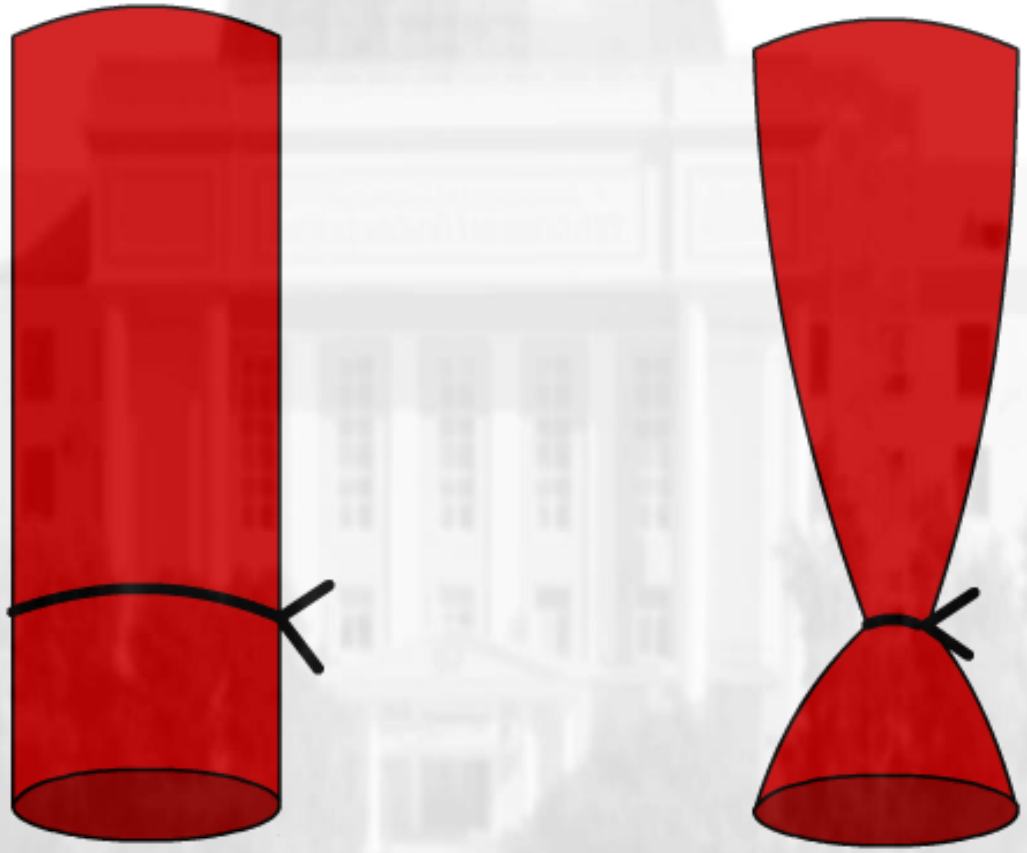

3rd century BC Antillus and Filagrius – a method of ligation of vascular aneurysms.

III век до н.э. Антиллус и Филагриус – метод лигирования аневризм сосудов.

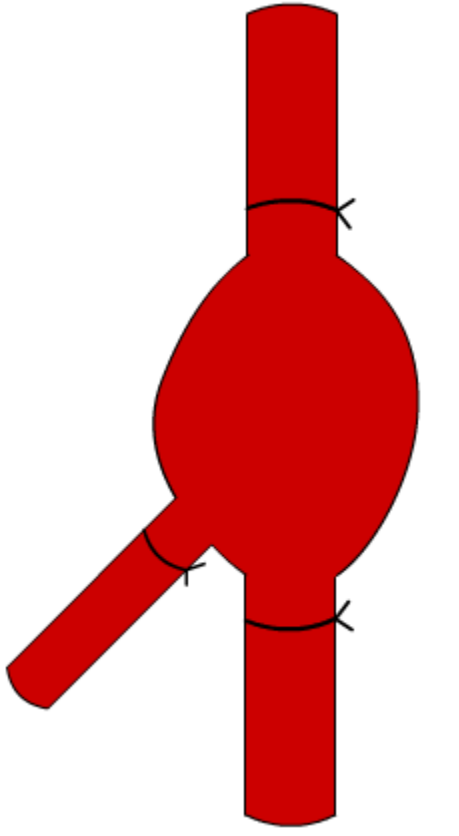

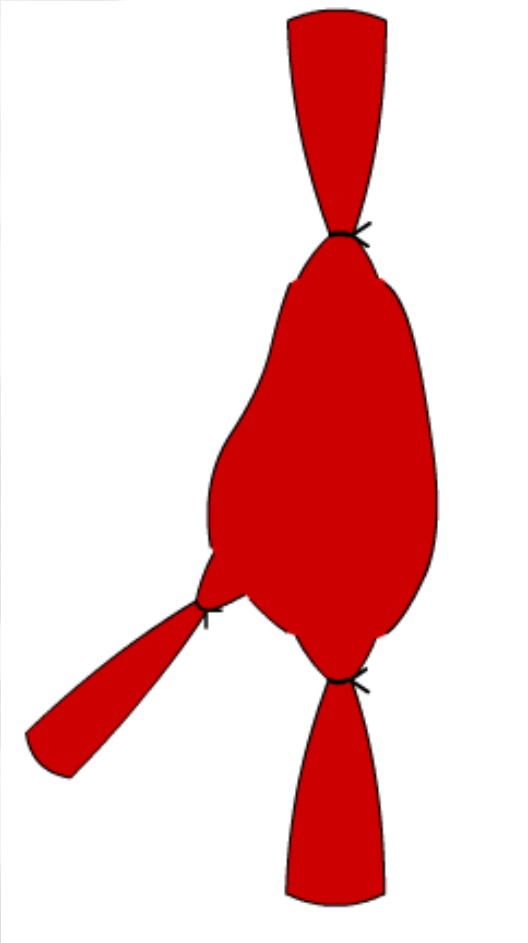

1530 Ambroise Pare – ligation of vessels outside the wound.

1530 г. Амбруаз Парэ – лигирование сосудов вне раны.

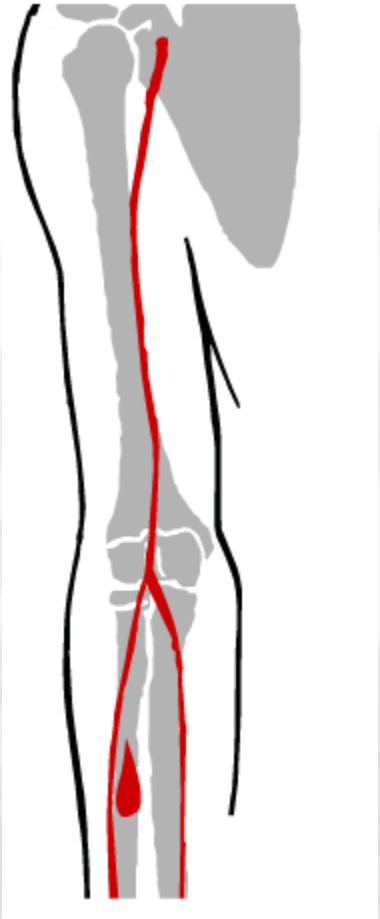

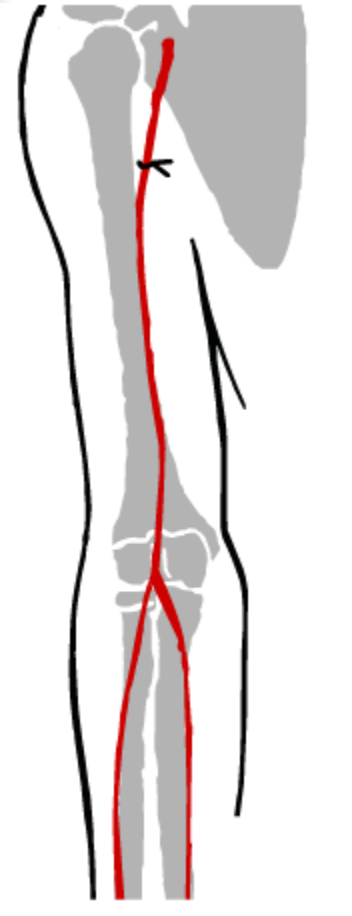

1743 Heller – indication of the presence of collaterals.
1780 Gunter – publication on the ligation of blood vessels throughout.
1809 Scarpa – dye injections confirming the presence of collaterals.
1823 I.V. Buyalsky – tables on operations of the main vessels.
1832 N.I. Pirogov – dissertation "Is the ligation of the abdominal aorta with an aneurysm of the inguinal region an easily feasible and safe intervention?"
1865 N.I. Pirogov – "The beginning of military field surgery" - the main provisions on operations of the main vessels.
XX century – development and improvement of vascular suture. A.I. Yasinovsky, P.I. Titov, N.I. Napalkov, I.F. Sabaneev, A.I. Morozova, A. Carrel, Payr.
1945-46 – Mechanical vascular suture. P.M. Androsov, V.F. Gudov, N.P. Petrova.
A great contribution to the development of vascular surgery in the USSR and abroad was made by: M.N. Anichkov, A.N. Bakulev, B.V. Petrovsky, A.A. Vishnevsky, P.A. Kupriyanov, Yu.E. Berezov, E.N. Meshalkin, B.A. Korolev, N.M. Amosov, B.V. Ognev, G.L. Ratner, A.V. Pokrovsky, M.E. De Bakey, D.A. Cooley, Ch. Dubost, Edwards, Hardy, Shumway.

Basic provisions on operations for injury of the main vessels (N.I. Pirogov, 1865).

Основные положения об операциях при ранении магистральных сосудов (Н.И. Пирогов, 1865)

1. If the neurovascular bundle is located between the muscles superficially (a. brachialis), the dissection is performed by retreating from the projection line (prevention of damage to the neurovascular bundle). *Если сосудисто-нервный пучок находится между мышцами поверхностно (a. brachialis), рассечение производить отступив от линии проекции (профилактика повреждения СНП).*

2. If the neurovascular bundle is located deep between the muscles (a. femoralis), the dissection is performed along the projection line. *Если сосудисто-нервный пучок находится между мышцами глубоко (a. femoralis), рассечение производить по линии проекции.*

3. If the neurovascular bundle is located deep under the muscles (a. tibialis posterior), the dissection is performed by retreating from the projection line. *Если сосудисто-нервный пучок находится под мышцами глубоко (a. tibialis posterior), рассечение производить отступив от линии проекции.*

Projection lines of large vessels
Проекционные линии крупных сосудов

Projection anatomy of the arteries of the upper limb
Проекционная анатомия артерий верхней конечности

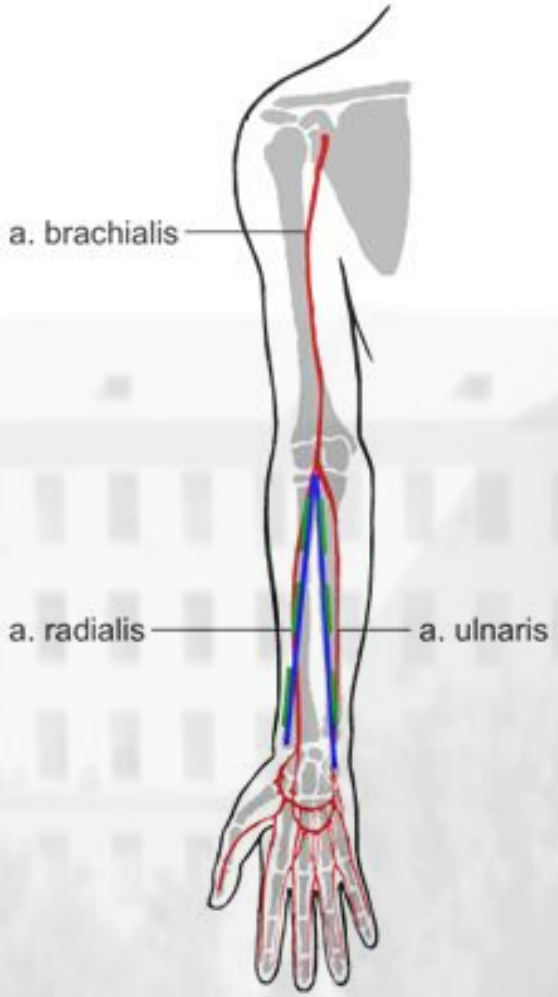

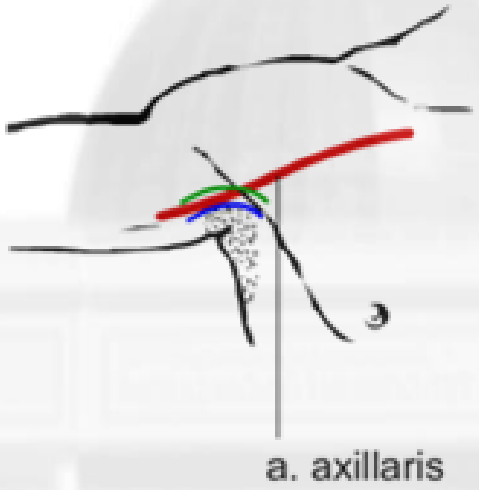

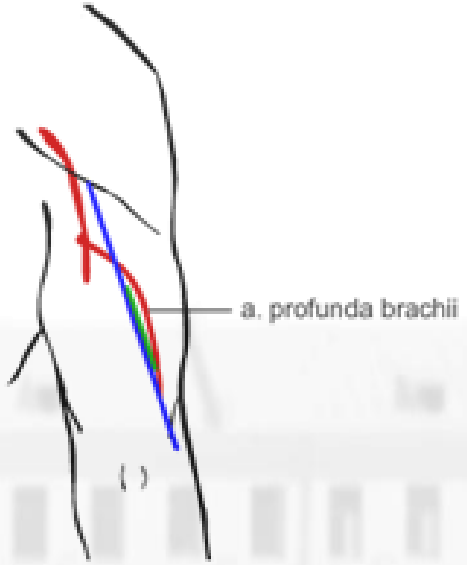

- projection line of the vessel, проекционная линия

- the incision line when accessing the vessel, линия доступа

Projection anatomy of the arteries of the lower limb
Проекционная анатомия артерий нижней конечности

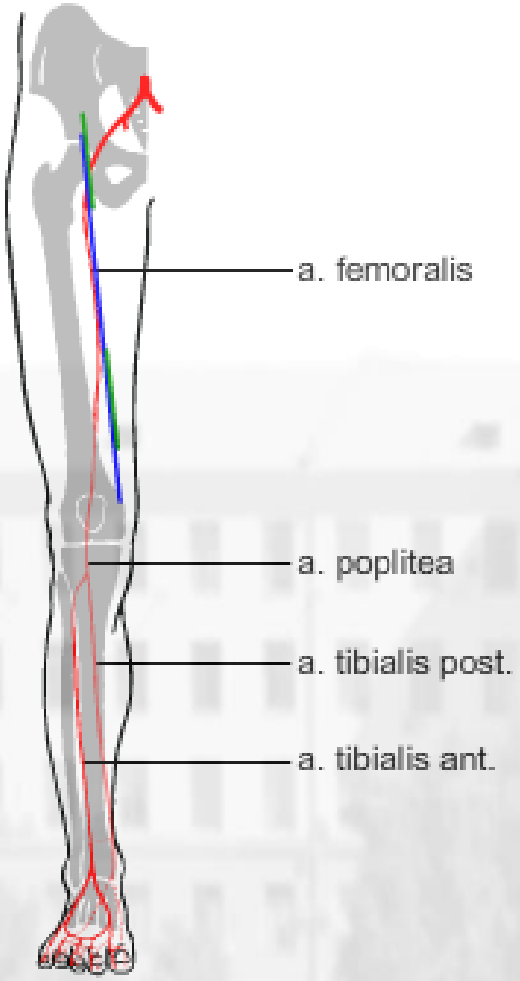

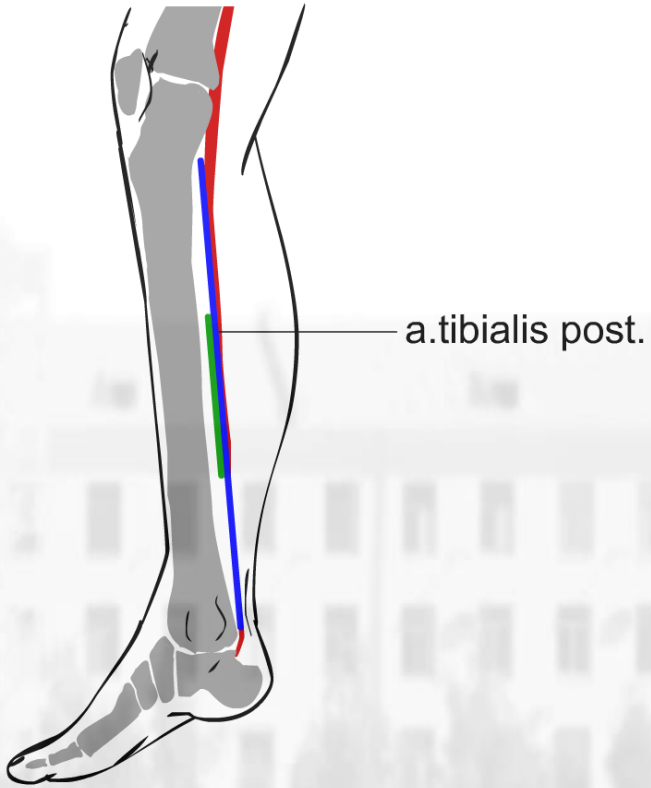

- projection line of the vessel, проекционная линия

- the incision line when accessing the vessel, линия доступа

Impaired blood flow and collateral formation

Нарушение кровотока и развитие коллатералей

Acute circulatory disorder
Резкое нарушение кровотока

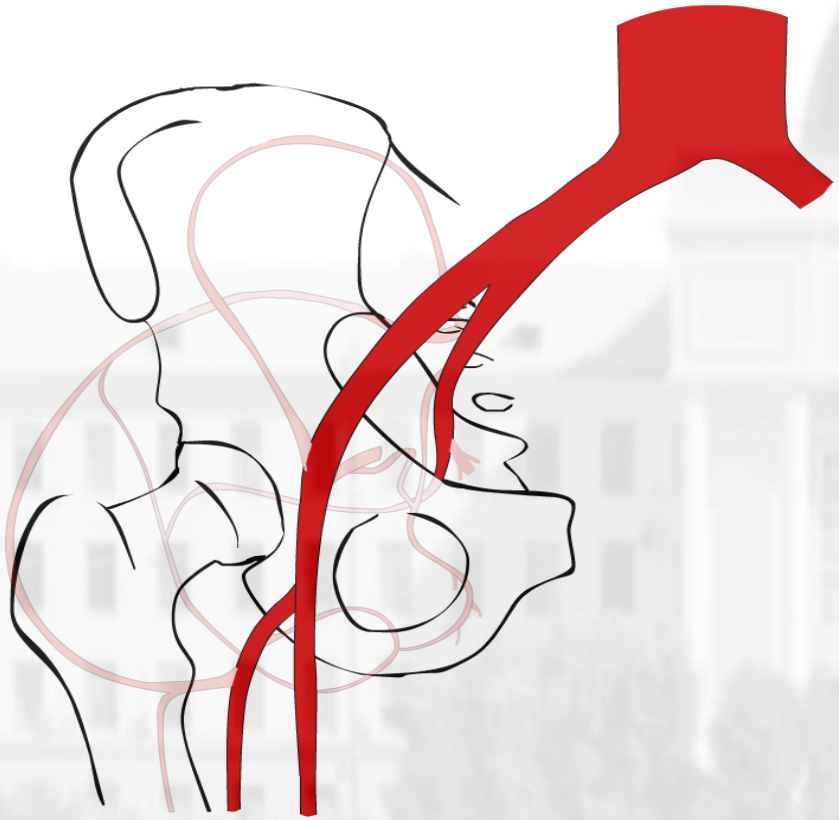

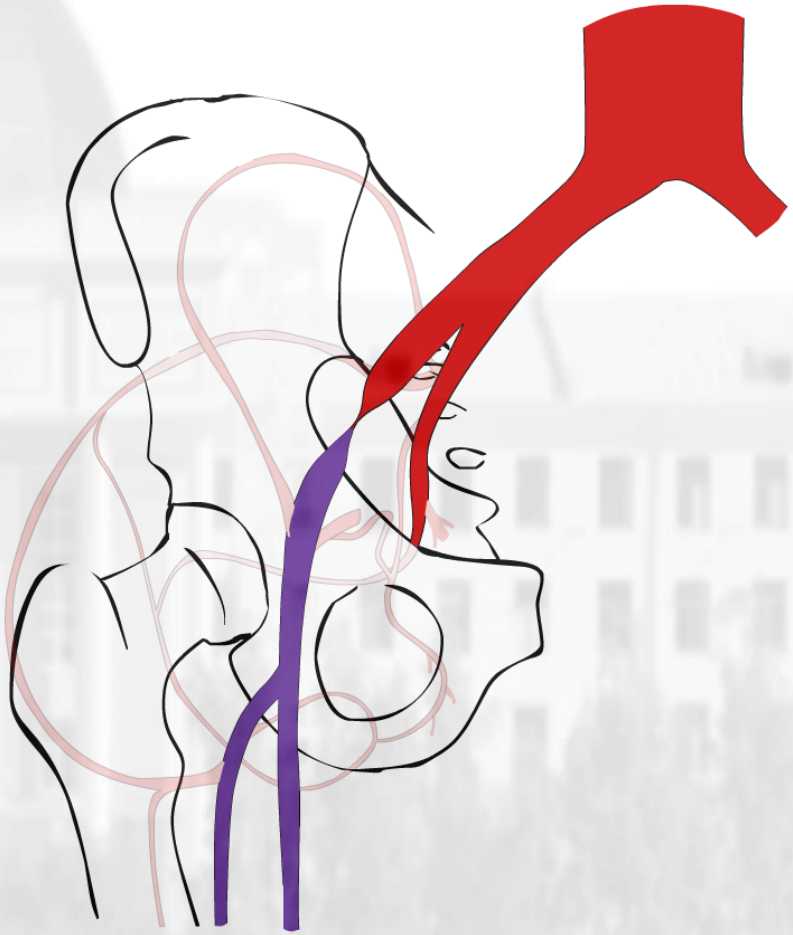

Acute circulatory disorder leads to necrosis. Collateral vessels do not have time to form

Gradual disruption of blood flow
Chronic circulatory disorder

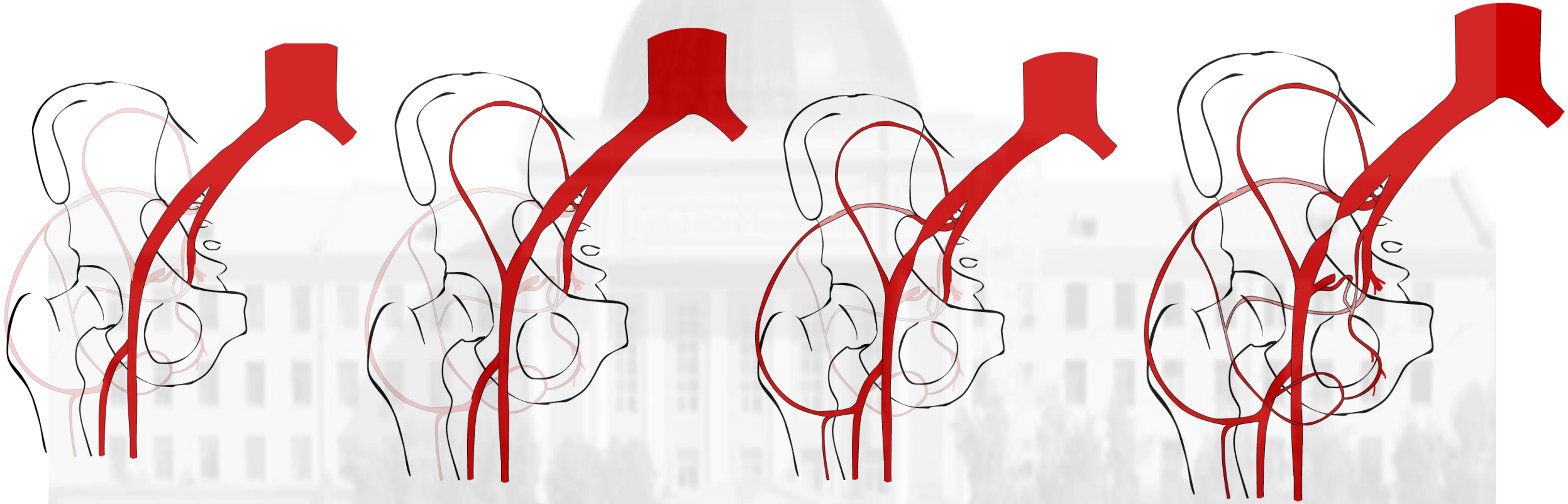

Components of effective collateral circulation:
Условия эффективного коллатерального кровообращения:

1. Diameter of collaterals. Диаметр коллатералей.

2. Presence of pre-existing collaterals. *Наличие предсуществующих коллатералей.*

3. The rapidity of blood flow disorders. *Быстрота нарушения кровотока.*

4. The degree of oxygen demand of the organ. *Степень потребности органа в кислороде.*

5. The general state of hemodynamics. *Общее состояние гемодинамики.*

Special vascular instruments
Специальные хирургические инструменты

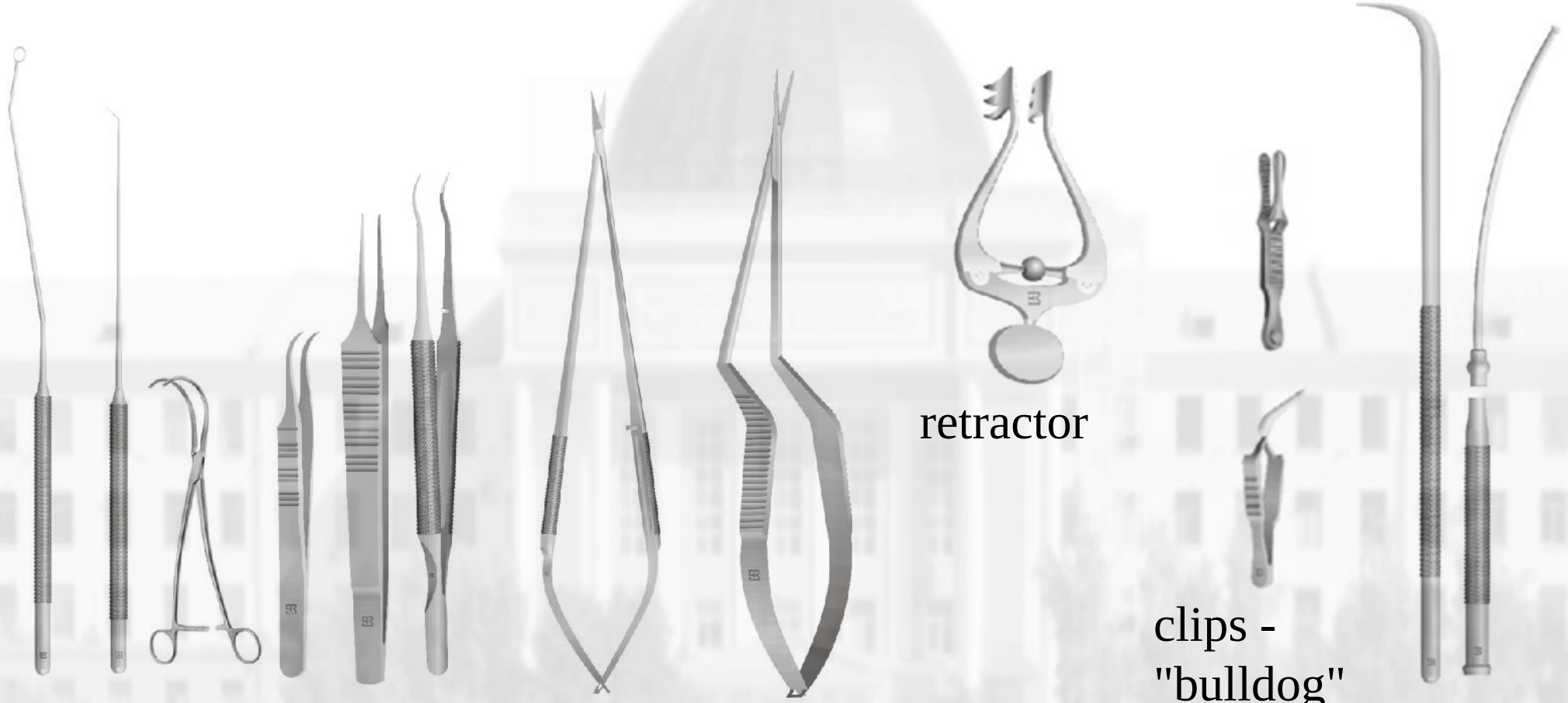

Instruments for ligation of large vessels
Инструменты для перевязки крупных сосудов

Deschanp's needle
Игла Дешана

Vascular curved dissector
Диссектор сосудистый изогнутый

Operations on vessels
Операции на сосудах

Requirements for vascular suture:
Требования, предъявляемые к сосудистому шву:

1. Strength. *Прочность*
2. Tightness. *Герметичность*
3. Asepticism. *Асептичность*
4. Atraumatic. *Атравматичность*
5. Absence of narrowing of the vessel lumen. *Отсутствие суживания просвета сосуда*
6. Absence of thrombosis. *Отсутствие тромбообразования*

Alexis Carrel (1873-1944)

1896. Graduated from the Lyon University of Medicine. As a student, in 1894 he witnessed the autopsy of the body of French President Sadi Carnot, who was killed by an anarchist. A knife wound to the liver and portal vein was found. Carrel incorrectly accused the surgeons of not saving the president's life. He stated that in order to save life, blood vessels should be sewn together in the same way as the edges of a wound are sewn together.
1900. He defended his doctoral dissertation on carcinomatous goiter.
1902. He completed a series of successful experiments on the development of an original vascular suture. I did not find like-minded people at the University of Lyon.

Wanting to become a practicing doctor, I was preparing for qualification exams. After two unsuccessful attempts to pass the exam, he was given to understand that due to racist beliefs he would fail for the third time.
1904. An employee of the University of Chicago. Together with C. Guthrie, he successfully studies auto- and allotransplantation in animals.
1906. Moves to work at the Rockefeller Institute of Medical Research, New York.
"10.10.1912. To award the Nobel Prize of the Year in Physiology and Medicine to Alexis Carrel in recognition of his work on vascular suturing and transplantation of vessels and organs."

Carrel Suture
Шов Карелля



Morozova’s Suture
Шов Морозовой



Rings of Donetsk D.A.
Кольца Донецкого



Intimendarteriectomy – removal of thickened intima with atherosclerotic masses in the narrowing area of the artery; performed on large vessels.
Интимэндартериоэктомия – удаление утолщенной интимы с атеросклеротическими массами в зоне сужения артерии; выполняется на крупных сосудах.

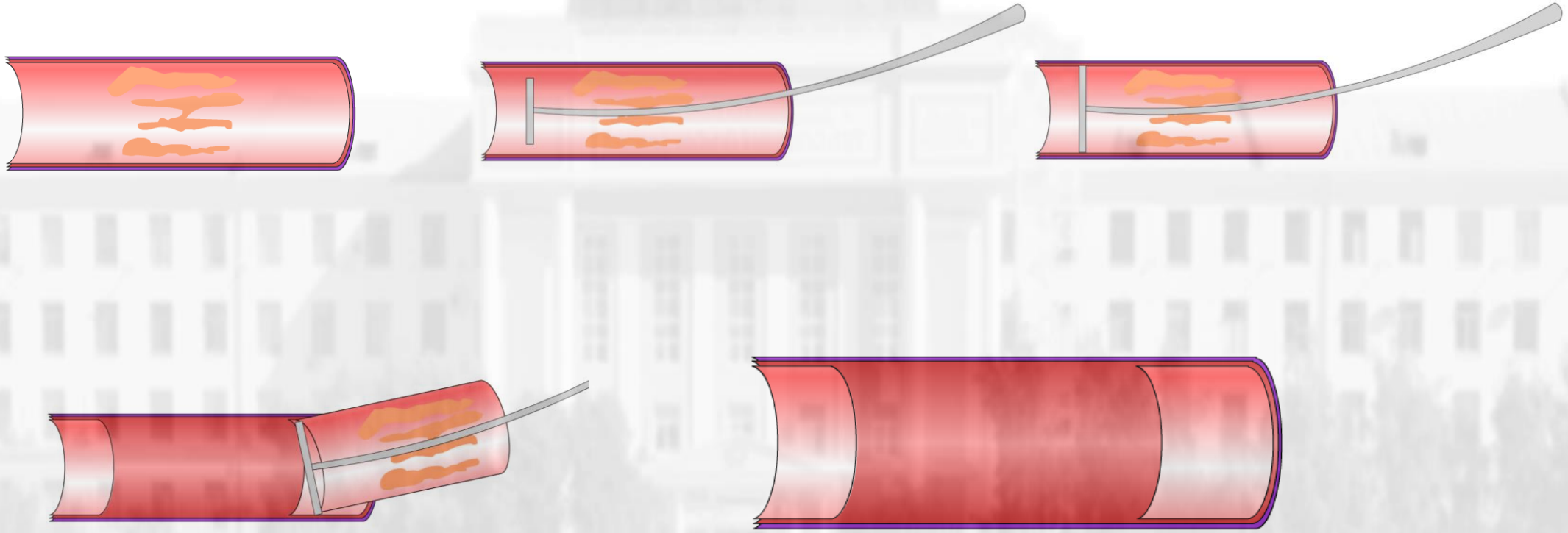

Prosthetics on vessels (angioplasty)
Протезирование на сосудах (ангиопластика)

Autoplasty is the use of the patient's own tissues as a plastic material. Arterial plasty is not performed, autoveins are used.
Аутопластика – использование в качестве пластического материала собственных тканей больного. Пластика артериями не производится, используются аутовены.
Regularities of venous autoplasty
Закономерности венозной аутопластики:

1. Replacement of large veins, whose patency is well compensated by collateral outflow of blood, is often accompanied by graft thrombosis. *Замещение крупных вен, нарушение проходимости которых хорошо компенсируются коллатеральным оттоком крови, часто сопровождается тромбозом трансплантата.*
2. The graft works well in the absence of collateral outflow. *Трансплантат работает хорошо при отсутствии коллатерального оттока.*
3. Passable venous grafts in 30-50% are initially thromboses. *Проходимые венозные трансплантаты в 30-50% первоначально тромбируются.*
4. Only a fresh venous graft fully takes root and retains the ability to grow. *Только свежий венозный трансплантат полностью приживается и сохраняет способность к росту.*
5. The presence of a small hematoma in the bed of the transplanted vein slows down the restoration of blood supply to its wall and is the cause of thrombosis. *Наличие небольшой гематомы в ложе пересаженной вены замедляет восстановление кровоснабжения ее стенки и является причиной тромбообразования*

Regularities of venous autoplasty:

Закономерности венозной аутопластики:

6. The use of anticoagulants may cause thrombosis. *Применение антикоагулянтов может вызвать тромбообразование.*

7. Plastic vessels of small diameter give poor results. *Пластика сосудов малого диаметра дает плохие результаты.*

Alloplasty is the replacement of vascular tissue within a single biological species. Satisfactory results were obtained when replacing large vessels. Venous plastic surgery gives unsatisfactory results (thrombosis, obliteration). *Аллопластика – замещение тканью сосудов в пределах одного биологического вида. Удовлетворительные результаты получены при замене крупных сосудов. Венозная пластика дает неудовлетворительные результаты (тромбоз, облитерация).*

Xenoplasty is the use for plasticizing animal tissues. Satisfactory results – when replacing large arterial vessels. Venous plastic surgery gives unsatisfactory results (thrombosis within 10 days). *Ксенопластика – использование для пластики тканей животных. Удовлетворительные результаты – при замене крупных артериальных сосудов. Венозная пластика дает неудовлетворительные результаты (тромбоз в течение 10 дней).*

Palliative operations.
Bypass shunting is the creation with the help of an artificial vessel (prosthesis) or autovein of an additional path for blood flow to bypass the existing obstacle.

Паллиативные операции.
Обходное шунтирование – создание с помощью искусственного сосуда (протеза) или аутовены дополнительного пути для кровотока в обход имеющегося препятствия.



Operations on the veins
Операции на венах

Troyanov-Trendelenburg operations. Isolation, ligation and excision in the subcutaneous fat of all veins flowing into the femoral vein. *Операции Троянова-Тренделенбурга. Выделение, перевязка и отсечение в подкожно-жировой клетчатке всех вен, впадающих в бедренную вену.*

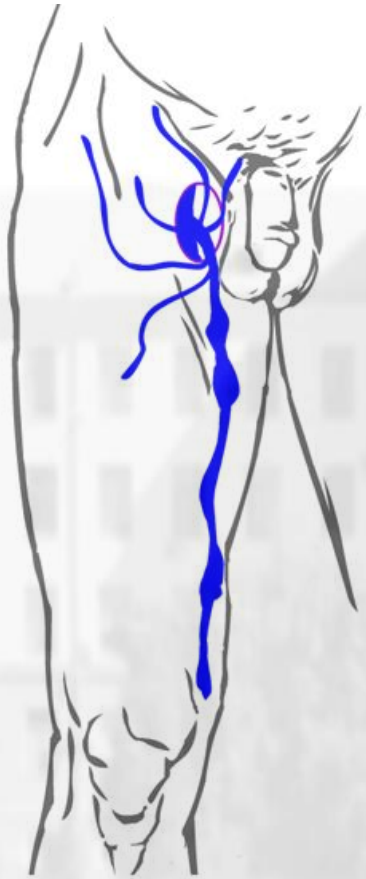

Babcock's operation. Removal of a large saphenous vein throughout the thigh. *Операция Бэбкока. Удаление большой подкожной вены на всем протяжении бедра.*

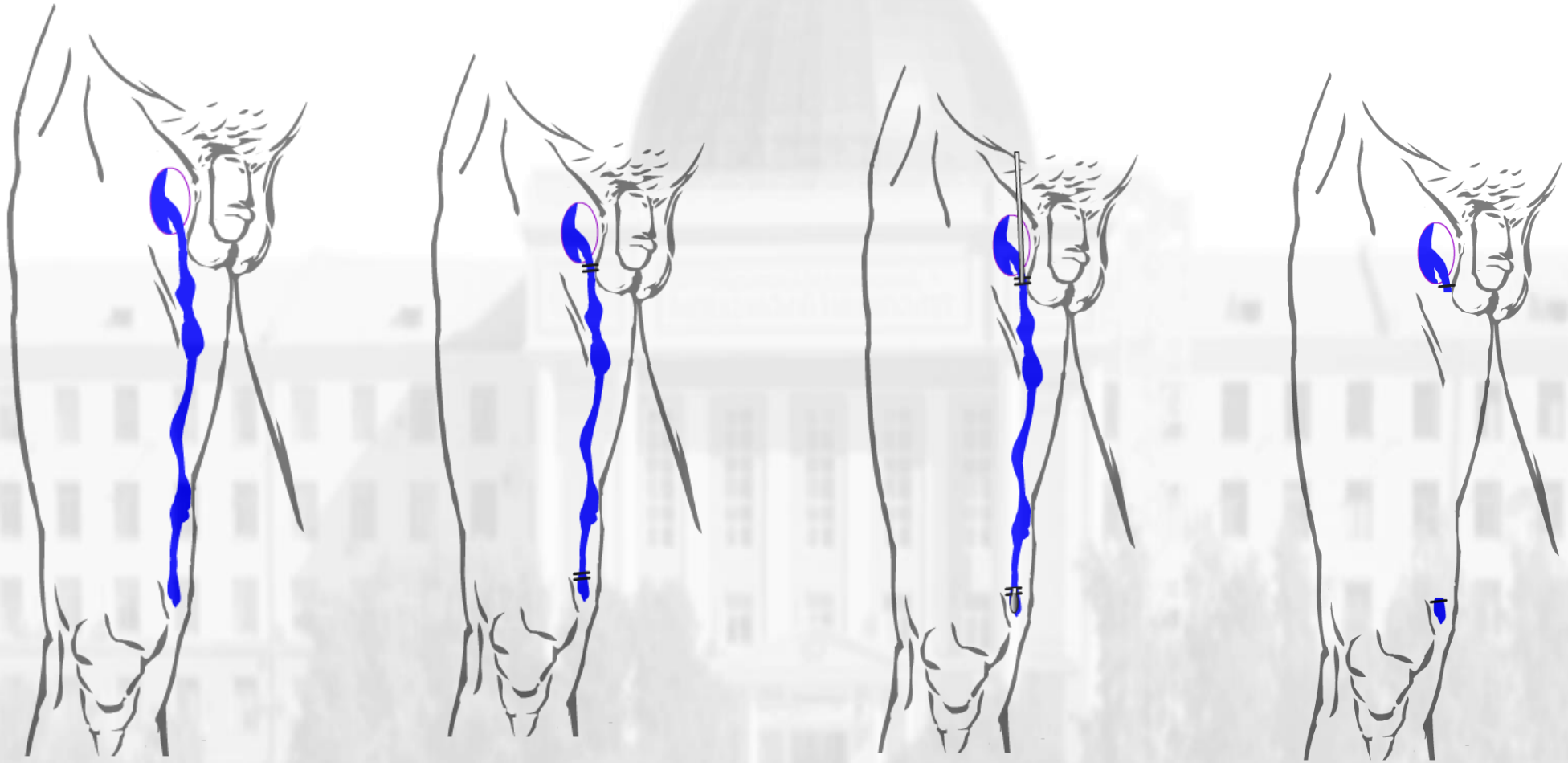

Operation Madelung. Removal of a large subcutaneous vein throughout the thigh through an incision in the skin and subcutaneous fat from the upper third of the thigh to the medial condyle of the femur. *Операция Маделунга. Удаление большой подкожной вены на всем протяжении бедра через разрез кожи и подкожно-жировой клетчатки от верхней трети бедра до медиального мыщелка бедренной кости.*

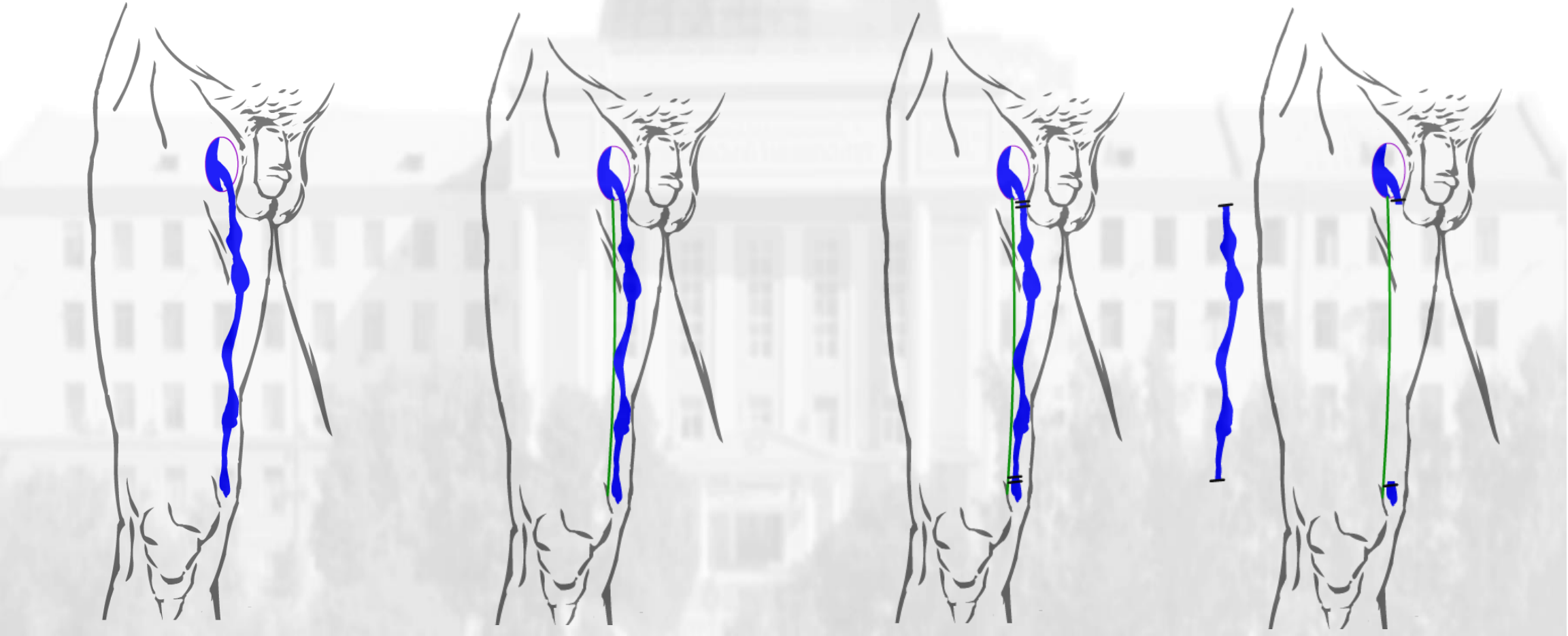

1. Operation of the Coquet. Ligation of all communicating veins epifascially.
Операция Коккета. *Перевязка всех коммуникантных вен эпифасциально.*
2. Linton's operation. Ligation of all communicating veins subfascially.
Операция Линтона. *Перевязка всех коммуникантных вен субфасциально.*

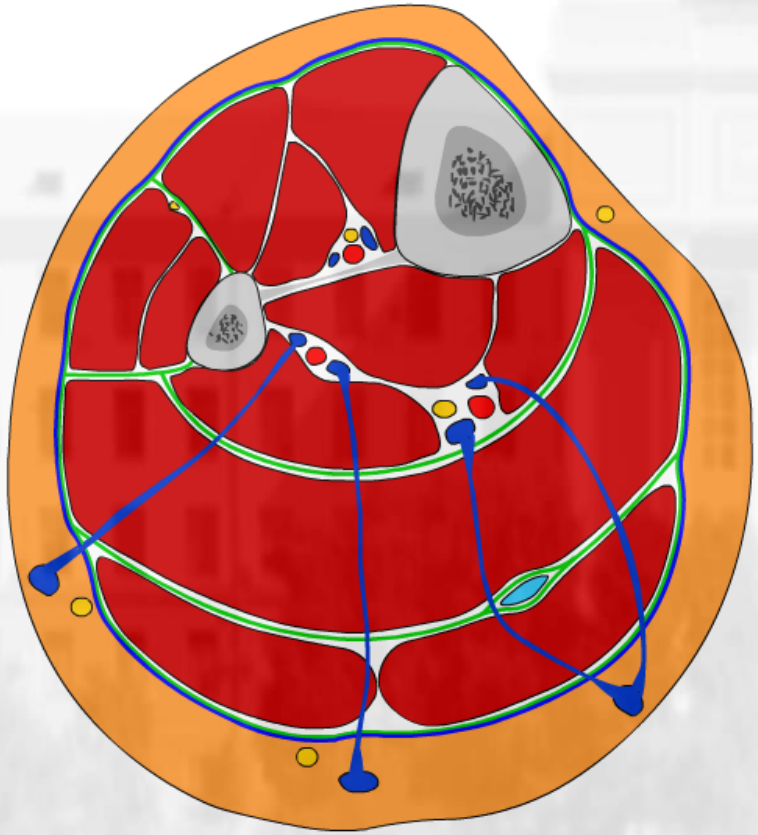

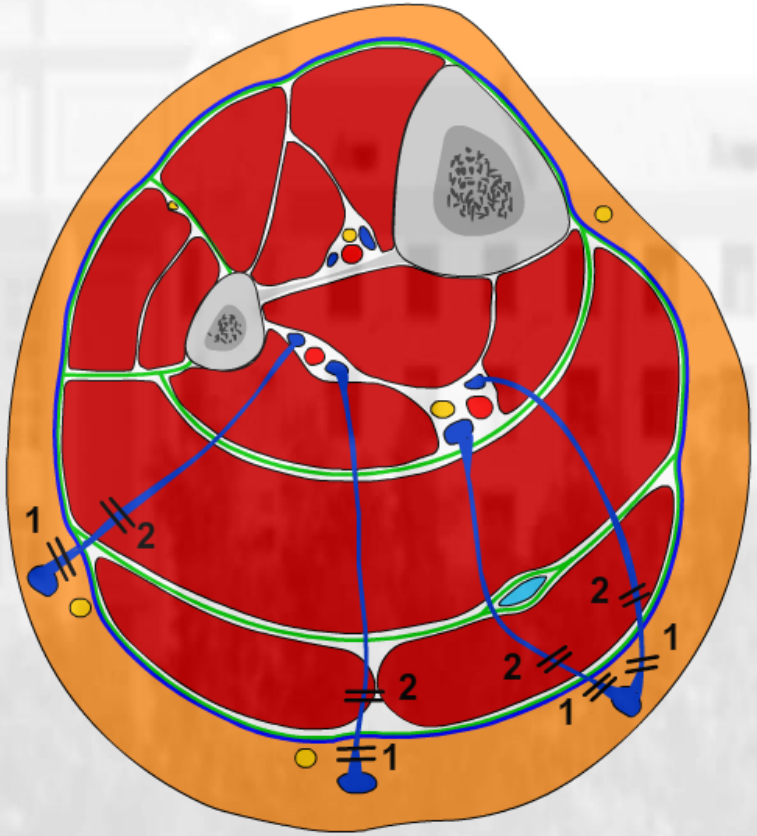

Operation Clapp. Applying compressive gauze swabs under the seam over the varicose nodes. Операция Клаппа. Наложение сдавливающих марлевых тампонов под шов над варикозными узлами.

Operations on the nerves
Операции на нервах

The most common operations on the nerve trunks: *Наиболее распространенные операции на нервных стволах:*

neurolysis;	невролиз;
neurorhaphy;	нейрорафия;
nerve resection;	резекция нерва;
neuroplasticity;	нейропластика;
neurotomy.	нейротомия.

Operations on the nerves
Операции на нервах

1. When the nerve is crossed in its peripheral segment, Waller's (Valler) degeneration of myelin fibers occurs. In the first 7 days after crossing, the nerve still seems to be alive: when it is irritated by current, the muscles innervated by it contract, but then fragmentation and resorption of myelin occurs. The Schwann sheath with nodes of Ranvier remains alive for a long time.
2. A complete violation of the conduction of the nerve fiber can be not only anatomical, but also functional.
3. Axons of the central segment of the nerve can grow into the axial cylinders of the peripheral segment. The rate of germination of nerve fibers is constant. On average, it is 1 mm per day or 2.5-3.0 cm per month.
4. Among the many reconstructive operations on the nerves, the worst results were obtained with all types of plastic replacement of defects using allo- or heterografts.
5. A nerve longer than 30 cm never fully recovers. During the 2 years required for nerve germination, irreversible degeneration of the distal muscles and tendons occurs, which requires orthopedic correction.

Operations on the nerves
Операции на нервах

The nerve suture technique includes 5 main steps.

Техника шва нерва включает 5 основных этапов:

Stage 1 - treatment of the ends of the nerve; usually with a sharp razor, 1-2 mm are cut from each end of the nerve;

Stage 2 - comparison of the ends of the nerve. The limb should be placed in such a position that the ends of the nerve are loosely adjacent to each other and can be sewn together without tension;

Stage 3 - the imposition of epineural sutures. Usually, two, less often four, sutures are sufficient to bring together the ends of the dissected nerve, leaving a gap between them of no more than 1-2 mm. You can not flash the nerve through its thickness. You can suture so that you get a cuff, as recommended by Richter;

Stage 4 - a month after the nerve is sutured, the limb should be gradually straightened and physiotherapy should begin;

Stage 5 - after 1-2 years, if necessary, orthopedic correction is performed: strengthening of the joints (arthrodesis, ankylosing), external prosthetics.

Operations on the nerves
Операции на нервах

If the operation after the intersection or injury of the nerve is performed in the long term, when a scar or neuroma has already formed, then a delayed suture is indicated, including excision of the neuroma, release of the nerve from the scar tissue (neurolysis) and suture of the nerve.

Operations on the tendons
Операции на сухожилиях

Operative interventions on tendons:

Наиболее распространенные операции на сухожилиях:

Tenoraffia.	Тенорафия.
Tenotomy.	Тенотомия.
Tenodesis.	Тенодез.
Tenolysis.	Тенолиз.

Requirements for tendon sutures:
Требования, предъявляемые к сухожильным швам:

1. The suture should be simple and technically easy to perform. *Шов должен быть простым и технически легко выполнимым.*

2. The suture should not significantly disrupt the blood supply to the tendon. *Шов не должен существенно нарушать кровоснабжение сухожилия.*

3. When suturing, it is necessary to maintain a smooth sliding surface of the tendon. *При наложении шва необходимо сохранить гладкую скользящую поверхность сухожилия.*

4. The suture should hold the ends of the tendons firmly and prevent them from splintering. *Шов должен крепко удерживать концы сухожилий и не допускать их разволокнения.*

Types of tendon sutures:
Виды сухожильных швов:

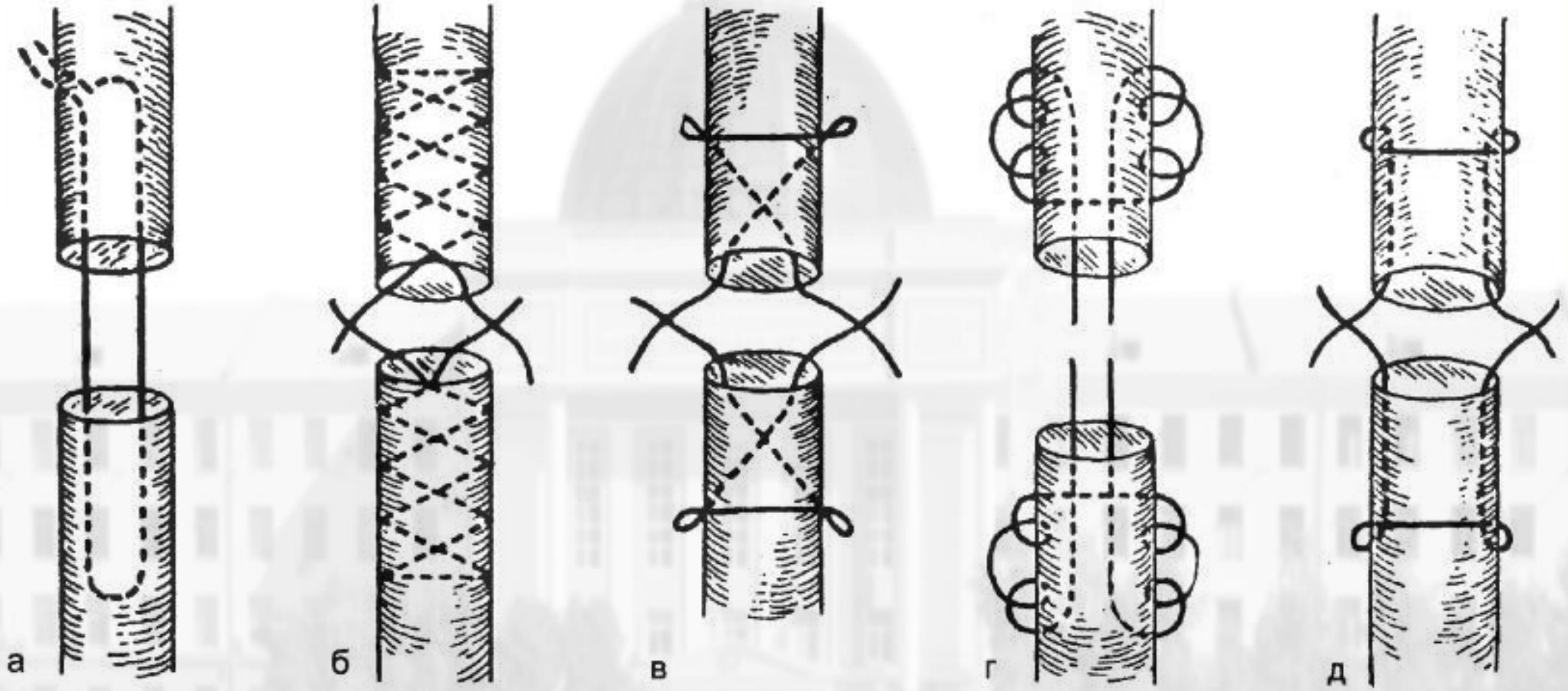

Suture Lange
Шов Ланге

Suture Cuneo
Шов Кюнео

Suture Bloch and Bonnet
Шов Блоха и Бонне

Kazakov’s Suture
Шов М.М. Казакова

Rozov’s Suture
Шов В.И. Розова

Thanks for your attention!